

See discussions, stats, and author profiles for this publication at: <https://www.researchgate.net/publication/352706466>

A better functional outcome with platelet rich plasma compared with local steroid injection in tennis elbow

Article in *IP International Journal of Orthopaedic Rheumatology* · January 2021

DOI: 10.18231/ijor.2021.006

CITATIONS

0

4 authors, including:



Shilp Verma

10 PUBLICATIONS 0 CITATIONS

[SEE PROFILE](#)



Alok Chandra Agrawal

All India Institute of Medical Sciences Raipur CG

130 PUBLICATIONS 69 CITATIONS

[SEE PROFILE](#)



Ankit Kumar Garg

All India Institute of Medical Sciences, Raipur

7 PUBLICATIONS 0 CITATIONS

[SEE PROFILE](#)

Some of the authors of this publication are also working on these related projects:



Femur Fracture [View project](#)

Content available at: <https://www.ipinnovative.com/open-access-journals>

IP International Journal of Orthopaedic Rheumatology

Journal homepage: www.ijor.org

Original Research Article

A better functional outcome with platelet rich plasma compared with local steroid injection in tennis elbow

Anwar A¹, Shilp Verma^{2,*}, Alok Chandra Agarwal², Ranjeet Choudhary², Ankit Kumar Garg²¹Dept. of Orthopedics, Kozhikode District Co-Operative Hospital, Kozhikode, Kerala, India²Dept. of Orthopedics, All India Institute of Medical Sciences, Raipur, Chhattisgarh, India

ARTICLE INFO

Article history:

Received 26-05-2021

Accepted 10-06-2021

Available online 24-06-2021

Keywords:

Platelet rich plasma

Steroid injection

Tennis elbow

ABSTRACT

Introduction: Lateral epicondylitis commonly referred to as 'tennis elbow,' is mainly observed in the 3rd and 4th decade of life in around 2% -3% of the population. Treatment modalities for lateral epicondylitis include analgesics, immobilization, tennis elbow brace, local steroid infiltration, and ultrasound therapy. Recent studies have explored the effectiveness of platelet-rich plasma (PRP) injections in lateral epicondylitis.

Materials and Methods: We used the block randomization technique. Two groups were prepared with 30 patients in each group. One group of patients received PRP and the other received local steroid injection. Patients were evaluated at the time of procedure and immediately after the procedure, at six weeks, three months, and six months, using the visual analog score and Liverpool's elbow score.

Results: At the end of 6 months, follow-up patients in the PRP injection group show good clinical and functional compare to the steroid group of patients.

Conclusion: PRP and local corticosteroid injection provide symptomatic relief in the treatment of lateral epicondylitis. PRP infiltration gives better results in pain relief and functional activities with statically significant values when compared with corticosteroid injections.

© This is an open access article distributed under the terms of the Creative Commons Attribution License (<https://creativecommons.org/licenses/by/4.0/>) which permits unrestricted use, distribution, and reproduction in any medium, provided the original author and source are credited.

1. Introduction

Lateral epicondylitis commonly referred to as 'tennis elbow' is mostly observed in the 3rd and 4th decade of life in around 2% -3% of the population. The cause of the disease is due to overload activity of extensors of the hand and abnormal pathological responses in the lateral epicondyle of the elbow at the common extensor tendon origin.¹ The tendon may sustain small tears which lead to fibrocartilaginous metaplasia, microscopic calcification, and finally a painful vascular reaction. Long term, this means there is disruption of the collagen matrix and the collagen repair cycle.²

Treatment modalities for the treatment of lateral epicondylitis include analgesics and immobilization. 90% of cases resolve spontaneously within 6-12 months. Other modalities for lateral epicondylitis include the use of a tennis elbow brace and working style modification. In persistent & recurrent cases, surgical intervention may be indicated such as the Homan's procedure or Garden's procedure.³

Recent studies have explored the use of PRP infiltration in the treatment of tennis elbow. PRP is derived from an autologous sample of blood and centrifuged to concentrate the various growth factors found in platelets such as transforming growth factor-beta (TGF-beta), Endothelial growth factor (EGF), Platelet-derived growth factor (PDGF), and Vascular endothelial growth factor (VEGF).^{1,4}

* Corresponding author.

E-mail address: drshilpverma@gmail.com (S. Verma).

This study will help us to know which amongst the two treatments (PRP and Corticosteroids) is more effective both subjectively and functionally.

1.1. Biomechanics

Extensor Carpi Radialis longus (ECRL) and Extensor Carpi Radialis Brevis (ECRB) counteract the flexion of the wrist and digits. The enhanced tone of ECRL and ECRB keeps the wrist in slight extension which permits the flexors of digits to function in their ideal maximum working length.– tension relationship, and thus generate maximal strength.⁵

1.2. Clinical history

The patient presented with acute or gradual onset of pain in the lateral aspect of the elbow, just distal to the lateral epicondyle. Clinical examination with tenderness present over the lateral epicondyle of the elbow. Cozen's test, Mills Manoeuvre, Chair lifting test, Maudley's test helps in the diagnosis.

2. Aims and Objectives

1. To evaluate the functional outcome and pain in tennis elbow patients treated with PRP and steroid infiltration.
2. To evaluate and compare the functional outcome in tennis elbow patients treated with PRP and steroid infiltration.

3. Materials and Methods

It is a prospective comparative study conducted in 60 adult patients (block randomized with 30 patients in each group) who presented in our opd with the clinical feature of lateral epicondylitis and who were not better with 6 weeks of conservative treatment were included after explaining the procedure with consent. Patients with type 2 diabetes mellitus, rheumatoid arthritis, or a history of trauma were not included in our group. Patients who have previously received an injection at the lateral epicondyle in the last 3 months were also excluded from the study.

3.1. Techniques

1. Corticosteroid injection technique-With a 10cc syringe, 2 ml of methylprednisolone acetate (Depo Medrol) is diluted with 5 ml of plain lignocaine. Under aseptic precaution, the lateral epicondyle is palpated and the injection is given perpendicular to it at the common extensor origin.⁶
2. PRP Technique: A sample of venous blood is collected from the patient's cubital vein and mixed with 4-5ml of anticoagulant (CPDA) to make a total volume of 20ml. It is then equally divided into 4 vacuum containers and centrifuged at 3500rpm for 7 minutes (Figure 1). The Buffy coat is aspirated from each container and the

collected sample is spun at 3000rpm for 5 minutes. Once again the Buffy coat is collected in a 5 ml syringe.¹ (Figure 2)

Patients are advised no strenuous activities of the affected for 7 days after the injection with only oral tramadol with paracetamol given for analgesia.

3.2. Statistical analysis

The data were analyzed using SPSS statistical software version 20.0. Categorical data were expressed in terms of rates, ratios, and percentages, and continuous variables were expressed as mean \pm standard deviation (SD). The comparison of mean VAS score and LES scores from enrolment to follow-up were compared by one-way ANOVA test. A 95% CI, the probability value of ≤ 0.050 was considered statistically significant.

4. Results

VAS scores in the PRP group before injection and at six weeks, three months, and six months showed a decrease in VAS scores with a mean difference of 1.6, 3, and 5.95 respectively which is statistically significant where p value < 0.001 . (Table 1). LES in PRP group scores between before injection and at six weeks, three months, and six months showed an increase LES score with a mean difference of 6.75, 8.4, and 11.65 which is statistically significant where p value < 0.001 . (Graph 1). VAS and LES score in corticosteroid group shows significant improvement in functional outcome and decreased in pain which is statistically significant where p value < 0.001 (Table 2)

Intergroup comparison of PRP group and corticosteroid group in visual analog scale at 6 weeks was higher in corticosteroids group with t value of 0.39 and was statistically not significant with a p -value 0.699. (Table 3) while VAS compared between pre-injection and at 3 months and 6 months was higher in the PRP group with a t value of 2.23 and 7.403 and was statistically significant with a p -value < 0.001 . (Graph 2) Intergroup comparison of PRP group and corticosteroid group in LES was compared between before injection and at six weeks, three months and six months was higher in PRP group with a t value of 6.007, 7.627 and 9.503 respectively and is statistically significant with a p -value < 0.001 . (Graph 3).

5. Discussion

PRP and Corticosteroid injection are common modes of treatment for lateral epicondylitis and other chronic tendinopathies⁸ which do not respond to conservative treatments. Literature has described the beneficial effects as well as equivocal results of each of these treatment modalities. Our study had assessed pain and functional outcome in patients who were given any one of these

Table 1: Intergroup comparison paired T with PRP Injection (VAS Score)

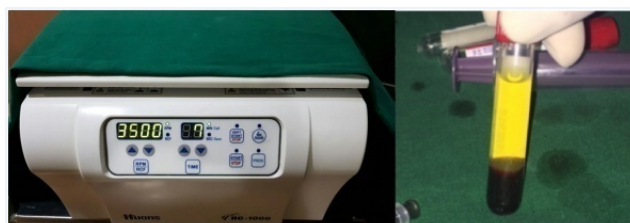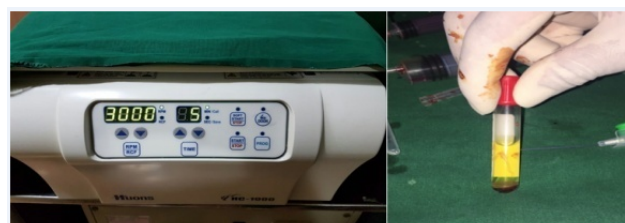		Mean	N	SD	Paired Differences Mean Difference	SD	T	Df	P Value
Pair 1	Pre Injection VAS (/10)	7.35	30	0.489	1.6	0.821	8.718	19	<0.001
	6 Weeks VAS (/10)	5.75	30	0.716					
Pair 2	Pre Injection VAS (/10)	7.35	30	0.489	3	1.376	9.747	19	<0.001
	3 Months VAS (/10)	4.35	30	1.387					
Pair 3	Pre injection VAS(/10)	7.35	30	0.489	5.95	1.099	24.211	19	<0.001
	6 Months VAS(/10)	1.4	30	0.94					

Table 2: Intergroup comparison paired T with corticosteroid Injection (LES Score)

		Mean	N	SD	Paired Differences Mean Differences	SD	T	Df	P value
Pair 4	Pre Injection LES(/53)	35	30	1.777	-2.45	1.959	5.592	19	<0.001
	6 Weeks LES(/53)	37.45	30	1.877					
Pair 5	Pre Injection LES(/53)	35	30	1.777	-2.75	1.943	6.329	19	<0.001
	3 Months LES(/53)	37.75	30	1.86					
Pair 6	Pre injection LES(/53)	35	30	1.777	-3.95	2.373	7.446	19	<0.001
	6 months LES(/53)	38.95	30	2.012					

Table 3: Intergroup comparison– Independent student t-test for VAS score

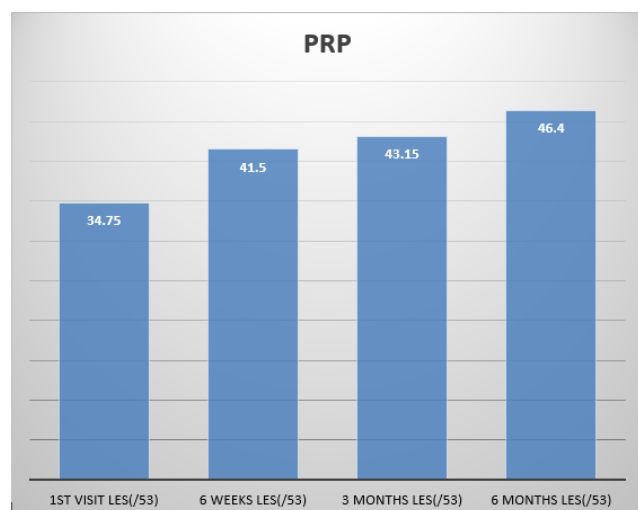
	Group	N	Mean	SD	T	Df	P value
VAS difference Pre injection and 6 weeks	PRP	30	1.6	0.82078	-0.39	38	0.699
	Corticosteroids	30	1.7	0.80131			
LES difference Pre injection and 6 weeks	PRP	30	6.75	2.53138	6.007	38	<0.001
	Corticosteroids	30	2.45	1.95946			
VAS difference Pre injection and 3 months	PRP	30	3	1.37649	2.23	38	0.032
	Corticosteroids	30	2.05	1.31689			
LES difference Pre injection and 3 months	PRP	30	8.4	2.68328	7.627	34.631	<0.001
	Corticosteroids	30	2.75	1.94327			
VAS difference Pre injection and 6 months	PRP	30	5.95	1.099	7.403	38	<0.001
	Corticosteroids	30	2.65	1.663			
LES difference Pre injection and 6 months	PRP	30	11.65	2.739	9.503	38	<0.001
	Corticosteroids	30	3.95	2.373			

**Fig. 1:** Centrifuge first spin: 3500RPM x7 minutes**Fig. 2:** Centrifuge second spin: 3000RPM x5 minutes

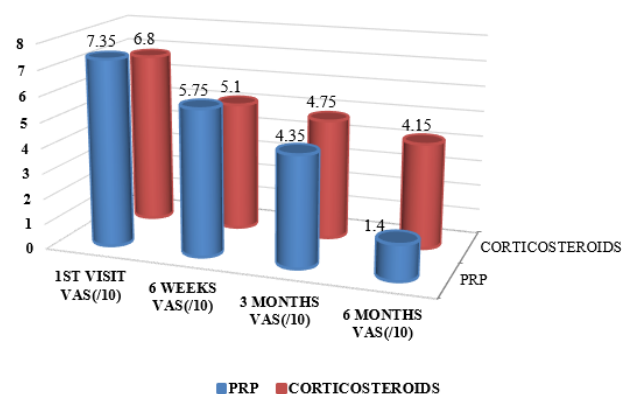
treatment modalities.

Thanasas C, Papadimitriou G, Charalambidis C, Papanikolaou A conducted a randomized control study on PRP with autologous whole Blood for treatment of tennis elbow in 28 patients under ultrasound guidance. Evaluation using a pain VAS and Liverpool elbow score was performed

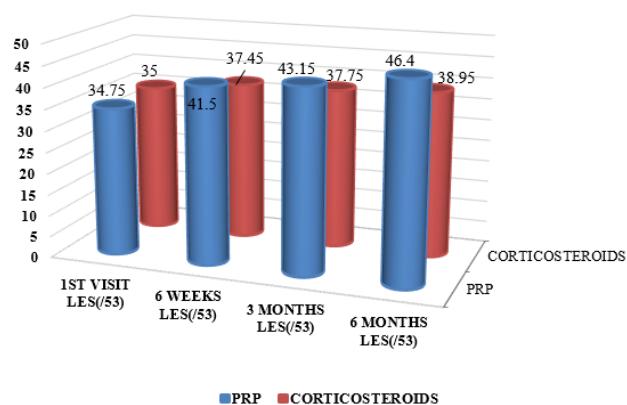
at six weeks, three months, and six months. The results showed significant improvement in the VAS score in the PRP injection group but did not show any difference in the Liverpool elbow score. They suggested that defining details of indications, best platelet-rich plasma concentration, number and time of injections, as well as rehabilitation



Graph 1: Intra group LES score comparison of PRP



Graph 2: Inter group comparison in VAS



Graph 3: Inter group comparison in LES

protocol might increase the method's effectiveness. Similar results were also observed in our study. Peerbooms JC, Sluimer J, Bruijn DJ, Gosens T² did a study on an effective good result in tennis elbow by a design of an RCT in 100 patients (51-PRP) and (49-corticosteroids). Patients were evaluated using the visual analog score (VAS) and a disability of arm, shoulder, and hand score after 1 year. The results concluded that PRP reduces pain and increases functions compared to corticosteroid injection.

In our study result of the intergroup comparison show that the VAS score in the corticosteroid group is better than the PRP group within the first 6 weeks. However, VAS was better with the PRP group in successive follow-up and was statistically significant. The intergroup comparison results of the LES score in the PRP group were statistically significant than the corticosteroid group in all the follow-up periods.

The improved results within the group between the follow-ups which is statistically significant in our study compared to other studies are possible because of the larger volume of PRP which we are injecting compared to the other study in which they give 3ml while we give 5 ml. While giving this 5 ml, we probably end up having more quantity of growth factors (Transforming Growth Factor, Vascular Endothelial Growth Factor, Fibroblast Growth Factor, Epidermal Growth Factor, Platelet-Derived Growth Factor).⁷ This possibly is giving better results compared to other studies. However, at the same time, there would be possibly more pain because of a large amount of PRP injecting into the patients on the day of injection. However, our methodology did not consider this and we have not recorded the VAS score on the day of injection to know whether there was an increasing amount of pain in patients treated with 5 ml of PRP injection.

Our study showed that there was statistically significant better functional and VAS score in patients treated with either PRP or corticosteroids, however, the PRP group had better functional outcome and good pain relief compared to corticosteroids infiltration.⁸

6. Conclusion

From our study it is evident that PRP provides symptomatic relief in the treatment of lateral epicondylitis, showing a significant decrease in VAS score and increase in LES score. Similarly, corticosteroid provides symptomatic relief in the treatment of lateral epicondylitis, showing a significant decrease in VAS score and increase in LES score. When comparing PRP and corticosteroid infiltration, platelet-rich plasma proved to be a more effective modality in the treatment of tennis elbow with a statistically significant better functional outcome and good pain relief.

7. Conflict of Interest

The authors declare that there are no conflicts of interest in this paper.

8. Source of Funding

This research did not receive any specific grant from funding agencies in the public, commercial, or not-for-profit sectors.

References

1. Thanasis C, Papadimitriou G, Charalambidis C, Paraskevopoulos I, Papanikolaou A. Platelet-Rich Plasma Versus Autologous Whole Blood for the Treatment of Chronic Lateral Elbow Epicondylitis. *Am J Sports Med.* 2011;39(10):2130–34. doi:10.1177/0363546511417113.
2. Peerbooms JC, Laar WV, Faber F, Schuller HM, Hoeven HVD, Gosens, et al. Use of PRP to treat plantar fasciitis: design of a multicentered. *BMC Musculoskelet Disord.* 2010;(11):69. doi:10.1186/1471-2474-11-69..
3. Zeisig E, Fahlstrom M, Ohberg L, Alfredson H. A 2 - year sonographic follow -up after intratendinous injection therapy in patients with lateral epicondylitis". *Br J Sports Med.* 2008;42(4):267–71.
4. Peerbooms JC, Sluimer J, Bruijn DJ, Gosens T. Positive Effect of an Autologous Platelet Concentrate in Lateral Epicondylitis in a Double-Blind Randomized Controlled Trial. *Br J Sports Med.* 2010;38(2):255–62. doi:10.1177/0363546509355445.
5. Faes M, van Elk N, de Lint J, Degens H, Kooloos JGM, Hopman MTE, et al. A Dynamic Extensor Brace Reduces Electromyographic Activity of Wrist Extensor Muscles in Patients With Lateral Epicondylalgia. *J Orthop Sports Phys Ther.* 2006;36(3):170–8. doi:10.2519/jospt.2006.36.3.170.
6. Krogh TP, Bartels EM, Ellingsen T, Buchbinder R, Fredberg U, Bliddal H, et al. Comparative effectiveness of injection therapies in lateral epicondylitis: a systematic review and network meta-analysis of randomized controlled trials". *Am J Sports Med.* 2013;41(6):1435–46.
7. Sampson S, Gerhardt M, Mandelbaum B. Platelet rich plasma injection grafts for musculoskeletal injuries: a review. *Curr Rev Musculoskelet Med.* 2008;1:165–74. doi:10.1007/s12178-008-9032-5.
8. Choudhary R, Chaudhary P, Sud A, Ramavat S. Efficacy Of Autologous Platelet rich Plasma Injection In Cases Of Proximal Plantar Fascitis Which Have Failed Conservative Management. *Int J Sci Res.* 2017;6(8):372–4.

Author biography

Anwar A, Medical Officer

Shilp Verma, Senior Resident

Alok Chandra Agarwal, Professor and HOD

Ranjeet Choudhary, Assistant Professor

Ankit Kumar Garg, Senior Resident

Cite this article: Anwar A, Verma S, Agarwal AC, Choudhary R, Garg AK. A better functional outcome with platelet rich plasma compared with local steroid injection in tennis elbow. *IP Int J Orthop Rheumatol* 2021;7(1):24–28.