

## Evidence-Based Regenerative Injection Therapy (Prolotherapy) in Sports Medicine

*K. Dean Reeves, MD; Bradley D. Fullerton, MD, FAAPMR; and Gaston Topol, MD*

### KEY POINTS

- The treatment of sports injuries to the point of restoration of full sports performance is an obvious goal in sports medicine. However, healing is the preferred goal because returning connective tissue to normal strength allows for a durable return to full sports performance.
- Regenerative injection therapy (prolotherapy) is the injection of growth factors or growth factor production stimulants to promote the regeneration of normal cells and tissue. Inflammation is not required, and scarring is not the result.
- Open-label clinical trials have been uniformly positive in outcome, but double-blind clinical trials have been hampered by a needling control that does not appear to be a placebo. Recent studies are making use of a noninjection control.
- Making use of consecutive patient data from athletes with career-threatening injuries (i.e., chronic groin strain in soccer or rugby players) that are not responsive to other treatments is a recommended study approach to assess regenerative injection therapy's ability to reverse otherwise permanent conditions. This is an avenue for the critical assessment of regenerative injection therapy's potential.
- Serial high-resolution ultrasound images are limited somewhat by uniformity of technique, but they offer a way to follow healing from regenerative injections.

### INTRODUCTION

The treatment of sports injuries to the point of restoration of full sports performance is an obvious goal in sports medicine. Healing, however, is the preferred goal because returning connective tissue to normal strength allows for a durable return to full sports performance.

Given the advancements in the knowledge of the degenerative nature of chronic sprain or strain and the ability of high-definition ultrasound to demonstrate the objective healing of soft tissue, the

use of prolotherapy, which is also called *regenerative injection therapy* (RIT), is expected to greatly accelerate in the next decade. This chapter will cover the pathology of injury; the current treatment methods and their limitations; and the rationale, basic science, and clinical studies of prolotherapy/RIT. In the latter section, it will also introduce two areas of particularly pertinent research approaches in sports medicine: the treatment of connective-tissue-based, career-threatening injuries and the use of high-resolution ultrasound to document healing.

### PATHOLOGY OF INJURY

During sports participations, tendons are subjected to unpredictable mechanical loads as they transmit forces to bone. Ligaments are likewise unpredictably stressed as they attempt to hold bony structures together at a fixed length. These mechanical loads, when excessive, lead to unhealthy changes in tendon or ligament structures. Numerous terms have been used to describe these unhealthy changes. *Tendinitis* implies inflammation, and *tendinosis* implies degeneration. Because inflammation and degeneration can only be confirmed via biopsy, the generic term *tendinopathy* is proposed as perhaps the best descriptive term.<sup>1</sup>

Mechanical testing of tendon specimens has provided a stress-strain curve, and this curve demonstrates that collagen fibers uncrimp by 2% stretch of a tendon and microscopically rupture beginning at 4% to 8% stretch. Beyond 8% stretch, macroscopic tears are noted, and, beyond 12%, complete rupture is likely.<sup>1</sup> Repetitive submaximal loading can cause microscopic injuries that, through the failure of individual collagen fibers, reduce the effective cross-sectional area of the tendon or ligament and thus make it more susceptible to failure.<sup>2</sup>

### CURRENT TREATMENT METHODS AND THEIR LIMITATIONS

Although the structure, composition, and mechanical properties of the tendon can change favorably in response to altered mechanical

loading conditions, that response is not consistently favorable, even in animal models. For example, although the strength of the insertion site may increase after long-term training,<sup>3</sup> the maximum stress of failure of the tendon may still decrease.<sup>4</sup>

Although appropriate training or exercise produces positive effects on tendons, long-term repetitive loading often produces inflammatory mediators such as prostaglandin E2 and degradative enzymes such as matrix metalloproteinase 1 and 3, even when loads are within the strength limits of the tendon.<sup>5</sup> Other factors such as vascular supply, age, and genetics can also contribute to tendinopathy, which helps explain how it can occur in sedentary people.<sup>6</sup>

It has been observed that rest is limited in its efficacy for bringing about healing in tendons in part because tendon metabolic activity is only 13% of muscle; this leads to an extended healing period that is not practical for the athlete.<sup>7</sup> Eccentric exercise appears to offer benefit in tendinopathy, and it has been used since the 1980s.<sup>8</sup> Mechanical loading with certain magnitudes and frequencies may enhance tendon repair and remodeling via fibroblast stimulation.<sup>9</sup>

The major goal of clinicians when treating acute musculoskeletal injuries is to return athletes to their preinjury level of function, ideally in the shortest time possible and without compromising tissue-level healing.<sup>10</sup> Inflammation can lead to the degradation of intact collagen and to viable cell death, thus potentially increasing the functional deficit and recovery period. Nonsteroidal anti-inflammatory drugs (NSAIDs) are the most frequently used pharmacologic substances for the treatment of tendinopathy.<sup>11</sup> It was logical years ago to assume, without rigorous clinical study or sufficient basic science backing, that inflammation might be harmful during healing, and thus treatment with anti-inflammatory medications or the injection of such should be helpful. However, it has been shown in animal studies that merely limiting neutrophil and leukocyte numbers after injury does not necessarily improve tendon function or strength.<sup>12</sup> A key issue is that many cellular and subcellular events that occur during the inflammatory response lead to the production and release of a plethora of growth factors that trigger the healing phase.<sup>13</sup> During the late 1990s, basic science evidence began accumulating about the negative effects of NSAIDs on fibroblast growth.<sup>14</sup> In 2001, Elder and colleagues published a sentinel article showing that a COX-2 inhibitor impaired the repair of the medial collateral ligament in rats after induced injury.<sup>15</sup> NSAIDs likely vary in their degree of inhibition of fibroblast growth, as Riley and colleagues showed with human patella and flexor tendon cells.<sup>16</sup> There is currently no randomized, controlled trial evidence of the tissue-level effects of cyclooxygenase inhibitors on acute musculoskeletal injuries.<sup>10</sup> Further questions regarding the use of these agents have been raised given the links between NSAIDs and adverse cardiovascular events.<sup>10</sup> It is fair to state that care needs to be taken before presumptively interfering with the natural processes of the healing cascade. It is now accepted that, when fracture healing or spine fusion is desired, NSAIDs should be avoided.<sup>17</sup> Current recommendations are to begin limiting the use of certain NSAIDs in soft-tissue injuries,<sup>18</sup> and, as nonselective NSAIDs are further investigated, these recommendations may expand. Cohen and colleagues' recent publication showing that both traditional and COX-specific NSAIDs significantly inhibited tendon-to-bone healing in a study of rotator cuff repair in rats is particularly sobering.<sup>19</sup> Given the questionable effects of oral anti-inflammatory drugs on soft tissue, it is understandable that the anti-inflammatory effects on critical growth factors are particularly profound if an anti-inflammatory solution is injected. Thus, the intratendinous injection of corticosteroids leads to negative rather than positive mechanical effects, such as reduced tensile strength and a loss of viscoelasticity in tendons.<sup>20,21</sup>

## CURRENT DEFINITION AND POPULAR NON-CONNECTIVE TISSUE USES OF PROLOTHERAPY/RIT

Since 1995, the definition of prolotherapy has changed.<sup>22</sup> The prior definition of prolotherapy concentrated on the injection of inflammatory solutions to induce growth. However, as our understanding of the direct use of growth factors and multiple ways to stimulate them has expanded, the definition of prolotherapy is best described simply as RIT, or, more specifically, as “the injection of growth factors or growth factor production stimulants to promote regeneration of normal cells and tissue.”<sup>23</sup> The most widespread form of RIT is the injection of erythrocyte growth factor (erythropoietin) to cause red cell proliferation in patients with chronic anemia and, more recently, in preparation for an acute loss of blood such as occurs during surgical procedures.<sup>24</sup>

At this point, the question has become more complicated: Although virtually all physicians are ordering the injection of growth factors for non-soft-tissue applications, what is the evidence for injection of growth factor or growth factor production stimulants in sports medicine conditions such as degeneration in tendons, ligaments, or cartilage?

### Growth stimulation through single growth-factor injection

Wang and colleagues describe the “application of growth factors that stimulate cell proliferation and extracellular matrix synthesis in tendinopathy,”<sup>25</sup> and they cited Molley and colleagues regarding this description.<sup>26</sup>

To confirm its practical usefulness, growth-factor injection should cause a microscopic or macroscopic change in structure, a measurable mechanical improvement in the local structure, and an improved functionality of the animal or human. All three of these have not been studied systematically for any single growth factor. However, primary publication findings do show the following:

#### *Microscopic or macroscopic change in structure from single growth-factor injection*

1. Improved collagen structure from the injection of insulin-like growth factor (IGF-1) in injured or degenerated animal tendons.<sup>27</sup>
2. Increase in the amount of tendon callus in transected rat Achilles tendon via the injection of bone morphogenetic proteins 13 and 14.<sup>28</sup>
3. Increase in cell proliferation and gene expression of procollagen types I and III when bone morphogenetic protein 12 is added to human patellar tendon fibroblast cultures.<sup>29</sup>

#### *Measurable mechanical improvement in the local structure due to a single growth-factor injection*

1. Improved tensile strength in transected tendons via the injection of cartilage-derived morphogenetic protein 2.<sup>30</sup>
2. Increase in failure load of transected and repaired Achilles tendon by a single injection of transforming growth factor  $\beta$ .<sup>31</sup>

#### *Improved pain or function of the animal or human via single growth-factor injection*

1. Improved walking pattern after the injection of IGF-1 in simulated Achilles-equivalent injury in rat tendon.<sup>32</sup>

**Summary of single growth-factor injection**

Single growth factor use has been studied at the animal level, but no single growth factor has been studied enough to demonstrate all key elements of macroscopic or macroscopic change in structure, improved mechanics, or improved pain or function in either animals or humans.

**Providing multiple simultaneous growth factors by injection: Emphasis on thrombin-stimulated platelet aggregates**

The most important complexity thus far discovered about growth factors is that they work in coordination and cooperation with each other. For example, IGF-1 primarily stimulates fibroblast migration and proliferation and increased collagen production; transforming growth factor  $\beta$  regulates cell migration and the binding tendencies of collagen; vascular endothelial growth factor is heavily related to angiogenesis; platelet-derived growth factor stimulates IGF-1 production and has a role in tissue remodeling; and basic fibroblast growth factor stimulates angiogenesis and regulates cell migration and proliferation. In addition, increasing the breaking energy of a healing tendon is a verifiable effect of several growth factors (IGF-1, transforming growth factor  $\beta$  and platelet-derived growth factor).<sup>26</sup> Tsubone and colleagues demonstrated that all major growth factors are expressed within 10 days after tendon injury but by different cell types and in different locations (i.e., some in tendon cells [platelet-derived growth factor, vascular endothelial growth factor] and some in inflammatory cells only [epidermal growth factor, IGF, basic fibroblast growth factor]).<sup>33</sup> Intervention with a growth-factor injection will ideally be done with an awareness of this healing timeline when each factor is expressed.

Injecting multiple growth factors simultaneously may be done with combinations of artificially produced (recombinant) growth factors. For example, Thomopoulos and colleagues demonstrated that platelet-derived growth factor BB and basic fibroblast growth factor in combination led to more proliferation effect than either factor demonstrated individually.<sup>34</sup> Another method of injecting multiple growth factors simultaneously is by injecting thrombin-activated platelet concentrates (platelet-rich plasma), which contain the chief growth factors for connective tissue. Platelet-rich plasma, when activated by thrombin, can also serve to stimulate further growth-factor production by cells that are exposed to the solution.<sup>35</sup> The results from the injection of thrombin-activated platelet concentrates are as follows.

**Microscopic or macroscopic changes in structure from the injection of multiple growth factors through thrombin-activated platelet aggregates**

1. Human tendon fibroblasts exposed to activated platelet concentration react by proliferation.<sup>35</sup>

**Measurable mechanical improvement in the local structure from the injection of multiple growth factors via thrombin-activated platelet aggregates**

1. After transection repair and the injection of platelet concentrate in postsurgical hematoma, the Achilles tendon equivalent in rats improved 30% more in strength and stiffness than did the control group.<sup>36</sup>
2. The normal patellar tendon of the rabbit, when injected directly with autologous blood, improved significantly in strength as compared with noninjected control tendon; it also maintained normal morphology.<sup>37</sup>

**Improved pain or function of the animal or human from the injection of multiple growth factors via thrombin-activated platelet aggregates**

1. In patients with refractory tennis elbow symptoms, autologous blood injections eliminated pain even during strenuous activity in 22 out of 28 subjects (LOE: D).<sup>38</sup>

**Summary of multiple growth-factor injection using thrombin-activated platelet aggregates**

The provision of multiple growth factors more closely simulates natural healing and is attainable via thrombin-activated platelet concentrate. Microscopic evidence of proliferation, measurable mechanical improvement in animals, and improved function in a human application (tennis elbow) have been described in recent studies but require repetition to confirm the results.

**Providing multiple simultaneous growth factors by stimulating their production: Emphasis on noninflammatory dextrose**

Diabetic research into the effects of elevated glucose levels on human fibroblasts and other cells has provided much of the in vitro basic science for such an alternative.

A normal human cell contains only 0.1% dextrose. Normal human cells, when exposed to an extracellular d-glucose (dextrose) concentration of as little as 0.5%, begin to produce platelet-derived growth factor,<sup>39</sup> transforming growth factor  $\beta$ ,<sup>40, 41</sup> epidermal growth factor,<sup>42</sup> basic fibroblast growth factor,<sup>43</sup> IGF,<sup>44</sup> and connective tissue growth factor.<sup>41</sup> Note that these growth factors are pertinent to the growth of tendon, ligament, and cartilage but not to bone.<sup>45</sup> Dextrose from 0.5% to 10% continues to be noninflammatory in nature. This is evidenced by the peripheral vein tolerance of hypertonic dextrose up to 10%. Ten percent dextrose has been studied sparingly because the standard concentration in clinical use for many years has been 12.5%, and it has generally been accepted (but not proven) that 12.5% dextrose is the minimum concentration that will stimulate the inflammatory cascade for a more vigorous growth effect. However, it is important to demonstrate that something as simple and ubiquitous in the body as dextrose, when concentrated, can create a stimulation of growth by noninflammatory means. In short, we truly have a prototype for noninflammatory, inexpensive growth stimulation. What we know about noninflammatory, dextrose growth is summarized by the following:

**Microscopic or macroscopic changes in structure due to noninflammatory dextrose exposure**

1. Cell proliferation and collagen synthesis increase has been demonstrated in human renal cortical fibroblasts (0.6% dextrose).<sup>46</sup>

**Measurable mechanical improvement in the local structure by the injection of noninflammatory dextrose**

1. In a pilot study, consecutive patients with anterior cruciate ligament laxity as measured by mechanical arthrometer (KT-1000) were injected with 9 mL of simple 10% dextrose at 0, 2, and 4 months. Subsequently, they were injected as needed if they were symptomatic at 6, 8, and 10 months (LOE: C).<sup>47</sup> Sixteen patients were included in this trial, and 14 of 16 had moderate to severe osteoarthritis as demonstrated by osteophyte formation and minimal (<3 mm) residual cartilage. Despite this, at 1 year, the difference in KT-1000-measured anterior displacement

from side to side improved 54%, and 9 out of 16 patients no longer tested as having laxity using standard KT-1000 criteria.

### **Improved pain or function of the animal or human from the injection of noninflammatory dextrose**

1. In the previously described study involving patients with anterior cruciate ligament laxity and concomitant knee osteoarthritis, patients were followed for 3 years using intention-to-treat criteria without data dropout. Walking pain improvement at 1 year was 40%, subjective swelling improved 52%, and range of motion improved by 14.1 degrees.
2. A double-blind, placebo-controlled study was conducted on patients with knee osteoarthritis (LOE: A).<sup>48</sup> One hundred eleven knees were injected with 9 mL of 10% dextrose at 0, 2, and 4 months. Knee pain had been present for an average of more than 8 years, an average of less than 3 mm of cartilage remained, and 35 out of 111 knees were bone on bone in at least one compartment. Walking pain reduced 35%, subjective swelling reduced by 45%, knee buckling episodes reduced by 67%, and range-of-motion improvement was 13.2 degrees with three injections of dextrose solution. Control solution injection led to improvements as well, but multivariate analysis demonstrated that the dextrose solution was superior ( $P = 0.028$ ).
3. A double-blind, placebo-controlled study of patients with finger osteoarthritis was also conducted (LOE: A).<sup>49</sup> Subjects were patients with finger osteoarthritis as determined by standard radiographic criteria and who had had pain for more than 5 years. In this study, symptomatic finger joints were injected with 0.25 to 0.5 mL of 10% dextrose on both sides of each joint at 0, 2, and 4 months; and this resulted in a 42% improvement in grip pain and 8 degrees of improvement in the flexion range of motion. The study demonstrated the superior results of dextrose as compared with placebo with regard to pain ( $P = 0.027$ ) and flexibility of joints ( $P = 0.003$ ) at 6 months.

### **Summary of basic science and clinical research on the injection of noninflammatory dextrose**

Dextrose elevation to as little as 0.6% in vitro stimulates human cells to produce key growth factors, and it has been demonstrated to cause cell proliferation in renal fibroblasts. In addition, it has been shown in pilot studies to tighten loose anterior cruciate ligaments and to be safe and probably effective therapeutically by two double-blind studies in patients with osteoarthritis. More basic science data and the repetition of double-blind studies are recommended. If simple dextrose stimulates the production of all key growth factors for ligament, tendon, and cartilage, it would be an inexpensive method of noninflammatory growth stimulation that may prove to be cost-effective for the long term.

### **Providing multiple simultaneous growth factors by stimulating their production: Emphasis on the use of brief inflammatory cascade activation**

Although the stimulation of growth without inflammation has some advantages, the most cost-effective approach to RIT may involve the use of the natural inflammatory route of growth factor stimulation. This inflammatory cascade is also briefly stimulated after a significant injury, but smaller (overuse) sports injuries create damage and do not stimulate the healing

cascade at all.<sup>25</sup> Thus, growth-factor production is either time limited or does not occur at all in many sports-related injuries. When the inflammatory cascade is stimulated by injury, cell death and tissue stretch need to be corrected. However, growth-factor stimulation by brief inflammation does not require significant damage to the tissue in question, and, thus, positive changes in structure and function can occur without having to correct the negative effects of injury. The primary solutions in clinical use for inflammatory cascade initiation have been dextrose 12.5% to 25% (which becomes inflammatory at those levels), phenol from 0.5% to 1.25%, and sodium morrhuate 0.1% to 1%. Research in the area of inflammation induction for repair has been hampered by limited research funding as a result of the inexpensive solutions being used; differences in technique among investigators sometimes leading to incorrect injection methods, which can be counterproductive (LOE: A)<sup>50</sup>; and the lack of a placebo control because the trauma of needling and microbleeding have led to significant benefit in a number of cases (LOE: B).<sup>51</sup>

### **Microscopic or macroscopic changes in structure after injection to briefly activate an inflammatory cascade**

1. After the injection of Sylnasol into the rabbit Achilles equivalent, 40% macroscopic thickening as compared with the opposite leg control at 9 months postinjection was seen.<sup>52</sup>
2. Macroscopic increase in the size of the attachment of rabbit Achilles tendon equivalent to bone was found 9 months after the injection of Sylnasol as compared with the opposite control leg.<sup>52</sup>
3. An increase in ligament fibril diameter of rabbit medial collateral ligament was demonstrated after injection with sodium morrhuate as compared with saline-injected control.<sup>53</sup>
4. An increase in the number of cells in rabbit patellar and Achilles tendons occurs when they are injected with sodium morrhuate as compared with saline-injected control.<sup>54</sup>

### **Measurable mechanical improvement in local structure after injection to briefly activate an inflammatory cascade**

1. Increases in thickness of 28%, in mass of 47%, and in ligament-to-bone-junction strength of 27% were seen in rabbit medial collateral ligament that was injected with sodium morrhuate as compared with saline-injected control.<sup>53</sup>
2. Increases in the diameter of rabbit patellar and Achilles tendons were seen when they were injected with sodium morrhuate as compared with saline-injected control.<sup>54</sup>
3. An increase in the strength of the rabbit patellar ligament of 36% was seen when it was injected once with sodium morrhuate 5% as compared with saline control.<sup>55</sup>
4. Injection of knees with phenol 1.25%, dextrose (glucose) 12.5%, and glycerin 12.5% (P2G)<sup>56</sup> resulted in a highly significant decrease in laxity, as measured by AP drawer testing with the Genucom knee apparatus.

### **Improved pain or function of the animal or human after injection to briefly activate an inflammatory cascade**

Many studies have been conducted, but only those with 25 or more patients, the name of the solution used, the percentage of improvement, and the percentage of patients with pain resolved or pain measured with a visual analog scale are summarized here.

1. Older case series in chronic back pain patients (not clearly stated as consecutive patients):
  - a. A subjective average pain improvement of more than 50% with Sylnasol injection was seen among 100 adults with low back pain and sacroiliac laxity (LOE: D).<sup>57</sup>
  - b. Complete pain relief was seen in 48% of 42 adults with low back pain who were injected with Sylnasol (LOE: D).<sup>58</sup>
  - c. The resolution of pain was seen in 82% of 267 adult patients with low back pain who were injected with Sylnasol/pontocaine or zinc/phenol (LOE: D).<sup>59</sup>
  - d. Among 136 adults with low back pain who were injected with P2G, 45% experienced pain relief of more than 75% (LOE: D).<sup>60</sup>
  - e. Of 43 adults with low back pain who were injected with sodium morrhuate, more than 75% pain relief was experienced by 72% of patients (LOE: D).<sup>61</sup>
2. Older case series in chronic neck or head pain patients (not clearly stated as consecutive patients):
  - a. Eighty-two patients with chronic neck sprain with pain were injected with P2G, and good to excellent pain reduction was seen in 82% of them (LOE: D).<sup>62</sup>
  - b. Three hundred twenty-two patients with posttraumatic headache with pain that had lasted an average of 4 years were injected with Sylnasol, phenol/dextrose/glycerine, or zinc sulfate. Good to excellent pain elimination was seen among 59% of these patients (LOE: D).<sup>63</sup>
3. Recent double-blind studies with clear methods in low back pain patients:
  - a. Eighty-one patients with chronic back pain were treated with P2G in lidocaine or with saline. Pain improvement of 60% as compared with 23% in control was seen at 6 months ( $P < 0.001$ ) (LOE: A).<sup>64</sup>
  - b. Chronic back pain in 81 patients was treated with P2G in lidocaine or saline with lidocaine. Pain improvement of 53% as compared with 38.5% in controls was seen at 6 months ( $P = 0.056$ ) (LOE: A).<sup>65</sup>
  - c. Chronic back pain in 74 patients was treated with P2G in lidocaine or 0.5% lidocaine in saline. Incorrect injection sites using inflammatory solution led to worse results in the active group (5% improvement in pain) and less than a placebo result in the control group (15% improvement in pain) (LOE: A).<sup>50</sup>
  - d. One hundred ten patients with chronic back pain were injected with dextrose 20% in 0.2% lidocaine or 0.2% lidocaine. Incomplete injection method with deep sacroiliac ligament not treated for four sessions and inferior sacroiliac and sacrospinous/sacroteruberous ligaments not treated. A more than 50% reduction in pain was noted among 46% of glucose patients as compared with 36% of control patients. This difference was not significant, but results were durable at 2 years in both groups, thus indicating strongly that needling has a therapeutic effect even without proliferant included in the solution (LOE: A).<sup>66</sup>

### Summary of basic science and clinical research on the injection of inflammatory proliferants

RIT using an inflammatory solution has received considerable clinical research attention for many years. Animal studies regarding microscopic and macroscopic changes are missing for dextrose and P2G, but they have been performed with sodium morrhuate. Mechanical changes in thickness, mass, and the strength of the ligament have been studied only with sodium morrhuate,<sup>53</sup> but tightening of knee laxity by an arthrometric measure has been demonstrated in a pilot study using P2G.<sup>56</sup> Case reports over many years demonstrate the safety of inflammatory solution

injection for both low back and neck pain, and they suggest efficacy.<sup>67</sup> However, double-blind studies with P2G or dextrose for back pain have been hampered by design flaws, including treatments simultaneous to injection,<sup>64,65</sup> incomplete injection technique,<sup>66</sup> improper patient selection leading to incorrect area injection,<sup>50</sup> a control that is not a placebo,<sup>50,64-66</sup> and the inclusion of patients who are receiving compensation for disability.<sup>50</sup> Nevertheless, treatment in each study resulted in considerable and sustainable improvement in pain and function. Similar to acupuncture and manipulation, true placebo controls for studies in RIT are difficult to design and expensive for investigators without usual funding sources for research.

### Using regenerative injection therapy for the treatment of connective-tissue-based, career-threatening injuries in sports medicine (example of inflammatory dextrose use)

Conditions that are critically blocking full performance in the athlete and that are not amenable to surgery or that would require long periods of sports cessation are suitable for consecutive patient study using noninflammatory or inflammatory proliferant solutions. An example is a study by Topol and colleagues of 24 consecutive elite athletes (22 rugby and 2 soccer) with career-threatening or, potentially, career-ending chronic groin pain preventing full sports participation that was nonresponsive to therapy with graded sports reintroduction.<sup>23</sup> Patients received monthly injection of 12.5% dextrose and 0.5% lidocaine in adductor and abdominal insertions and the symphysis pubis, depending on palpation tenderness. Injections were given until complete resolution or lack of improvement for two consecutive treatments occurred. A mean of 2.8 treatments were given. A reduction in the visual analog pain scale score for pain with sports was from a mean of 6.3 to 1.0 ( $P < 0.0001$ ), and the reduction in the Nirschl pain phase scale score was from 5.25 to 0.79 ( $P < 0.0001$ ). Twenty out of 24 patients had no pain in the groin at an average follow-up time of 17 months, and 22 out of 24 patients were no longer restricted with regard to sports participation, with a success rate of return to elite sports of 92% (LOE: D).

Further such studies are forthcoming and will likely involve the use of brief inflammatory cascade stimulation; this appears to be not only economical and safe, but it also has been the best studied in both animals and humans.

### Use of high-resolution ultrasound to document changes after proliferant injection

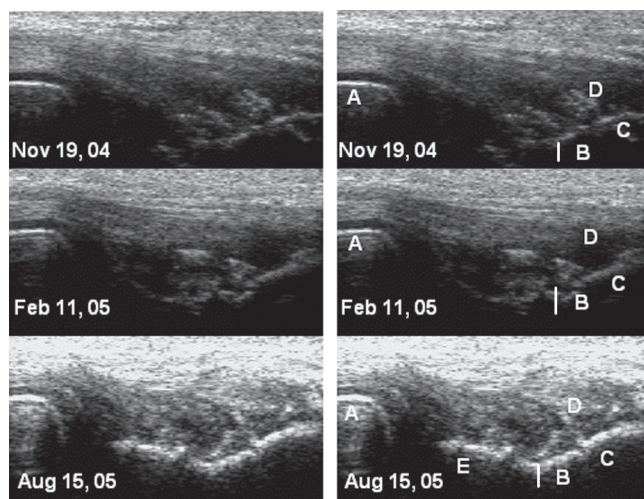
#### Case 1: Complete Achilles tendon rupture

A sectional study was recently published by Lazzara using radiographic imaging (magnetic resonance imaging and high-resolution ultrasound) to document healing (LOE: E).<sup>68</sup> The subject was a 26-year-old former European national soccer player who, during a soccer tournament, ruptured her Achilles tendon with a 1.1-cm gap; this was treated with casting in plantarflexion and no weight bearing for 60 days. The player refused surgery against medical advice, and she opted for proliferant injection. Strict avoidance of weight bearing was continued, and RIT was performed approximately every 10 days for 8 treatments over 3 months using 15% dextrose and 3.75% sodium morrhuate. Palpable filling in of the gap was noted by the second treatment visit, and, by 6 weeks (after three treatments), high-resolution ultrasound demonstrated newly formed tendon bridging the gap. Magnetic resonance imaging obtained at the tenth week after treatment onset showed an intact Achilles tendon. The athlete was jogging and aggressively stretching her Achilles tendon by 4 months. Clearly this was an instance in which surgery was the preferred alternative for treatment, and yet it serves to illustrate the potential for radiographic confirmation of soft-tissue

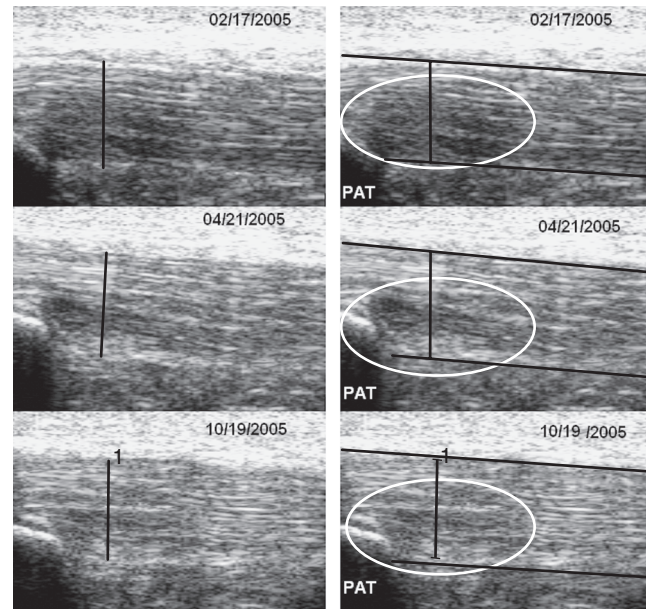
healing by brief inflammatory cascade stimulation. Radiographic findings are found in the original source manuscript, but the following cases have ultrasound images available.

### Case 2: A 61-year-old male golfer with extensor tendinosis

This patient had 3 years of left lateral elbow pain and 2 years of extension deficit in his elbow range, and he had received 3 steroid injections. His chief complaint was difficulty playing golf. On examination, he had a firm end feel to extension at  $-10$  degrees, and there was pain over the common extensor insertion and the radial head. Magnetic resonance imaging was diagnostic for common extensor tendinosis. **Figure 50.1** shows a high-resolution ultrasound of the elbow in pronation at three different points in time. The images on the left and right are identical, but the images on the right are labeled anatomically: *A* is the radial head; the line labeled *B* is the bony narrowing between the lateral epicondyle and the capitulum of the humerus (the rounded portion of the end of the humerus that articulates with the radial head); *C* represents movement up the bone toward the lateral epicondyle; and *E*, which is only seen clearly in the bottom right view, is along the side of the capitulum of the humerus, which is better seen after proliferant injection. This patient received 9 injection sessions beginning on November 29, 2004. Several treatments were with dextrose 15%, and two included 0.5% sodium morrhuate. Common extensor entheses, annular ligament, radial collateral ligament, and capsular entheses were injected. The clinical result by August 15, 2005, was an extension range gain to  $-2$  to  $-3$  degrees, no pain on palpation, and no functional limitations. The serial ultrasounds demonstrate hypoechoic (dark) areas of tissue separation or insufficiency and edema (*D* is the common extensor tendon). By the time of the ultrasound on August 15, the entire region above the bones was more densely populated with organized connective tissue fibers. It is interesting to note that the capitulum (although it is not seen well on the first two ultrasounds) appears to move closer to the radial head, and dynamic ultrasound showed that radial head subluxation ceased as treatment progressed. This appears to correlate with the range-of-motion loss at treatment onset that also resolved with treatment. Note also that, although bony growth factors are not stimulated by injection, the typical effects after treatment with proliferant include a periosteal reaction that allows for the better visualization of contours of bone and an increased echogenicity of the soft tissue as edema resolves and tissue becomes more tightly packed.



**Figure 50.1** Extensor tendinosis changes with regenerative injection therapy.



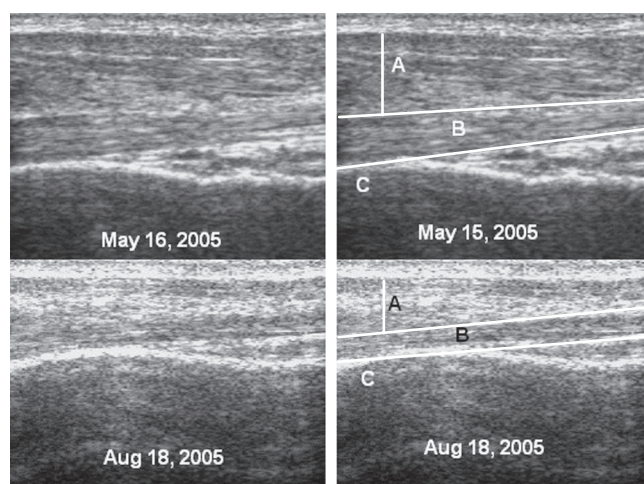
**Figure 50.2** Patellar tendinosis changes with regenerative injection therapy.

### Case 3: A cyclist with patellar tendinosis

A 40-year-old male competitive cyclist was first seen in November 2004 because he could not run or handle rough terrain or sustained hills as a result of knee pain. He had history of remote distal realignments (patellofemoral tracking type surgery). Pain was at the inferior patella and over the tibial tuberosity. He was treated on February 17, 2005, and April 21, 2005, with an injection of 15% dextrose over the patellar tendon origin on the inferior patella pole and its insertion over the tibial tuberosity. Complete symptom resolution occurred with the last follow-up evaluation on January 23, 2006, at which point the patient was training for the racing season. **Figure 50.2** shows a high-resolution ultrasound at the time of the first two sessions and at 6-month follow-up on October 19, 2005. On the right side of the figure are the same images but with red outlining the patellar tendon to depict its thickness. In addition, the yellow circle surrounds an area of hypoechoic tissue. From February 17, 2005, through October 19, 2005, an increase in the echogenicity of the tendon is demonstrated.

### Case 4: An 85-year-old male patient with bicipital tendinosis

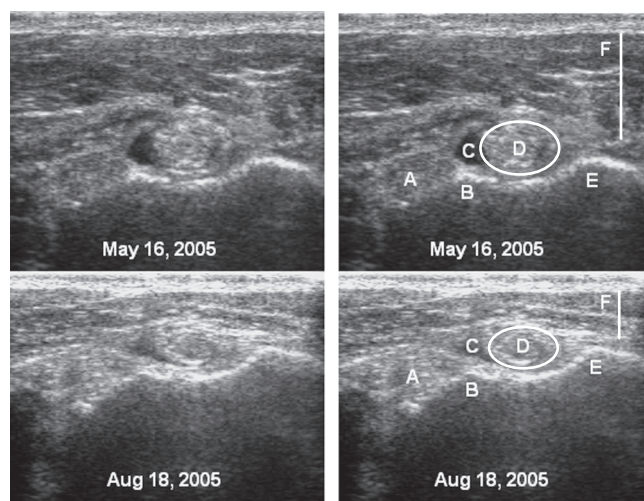
Although this patient was not an athlete in the competitive sense, he was quite active for 85 years of age. This patient had chronic, worsening anterior shoulder pain. The initial examination on May 16, 2005, showed that the bicipital tendon and the surrounding region were painful to palpation. The patient received three treatments consisting of the injection of 15% dextrose around the bicipital region on May 27, June 17, and July 8, 2005, without regard for whether the injections were precisely extratendinous or intratendinous because the injections are always given on bone in successive rows. **Figure 50.3** shows a longitudinal ultrasound through the bicipital tendon at the time of the first evaluation and at follow-up on August 18, 2005. On the right side are the labeled images. Deltoid muscle thickness is represented by *A* in the figure, and the degree of decrease in the swelling in the deltoid is easily seen by the decrease in thickness by August 18. The long head of the bicipital tendon is outlined in yellow on the right, and,



**Figure 50.3** Biceps tendinosis changes with regenerative injection therapy (longitudinal view).

between May and August, the tendon changes shape to become more linear as edema decreases in the proximal portion. Again, an echogenicity increase throughout the region is seen. The point marked *C* is the proximal humerus at the distal onset of the bicipital groove. **Figure 50.4** is a transverse ultrasound image at the distal bicipital groove showing the subscapularis entheses as *A*, the lesser tubercle at *B*, the greater tubercle labeled *E*, and the deltoid thickness labeled *F*. The area labeled *C* is a hypoechoic area just outside the biceps tendon, and it is seen to decrease in echogenicity between May 16 and August 18, 2005. The point marked *D* is the biceps tendon itself in transverse view. The decrease in edema both in the overlying tissue and in the tendon itself is clearly seen along with an increase in the density of the bicipital tendon.

Cases 2 through 4 were performed in the same clinic by the same clinician. At each follow-up, the ultrasound examination, the patient position, the probe pressure, and the machine settings (including transmit and gain) were reproduced exactly as they had been during the prior study. In other words, the amount of sound transmitted by the probe was the same at each study; thus, the increase in tissue signal is felt to be related solely to an increase in tissue density.



**Figure 50.4** Biceps tendinosis changes with regenerative injection therapy (transverse view).

## SUMMARY OF BASIC SCIENCE AND CLINICAL WORK IN PROLOTHERAPY/REGENERATIVE INJECTION THERAPY

Single growth-factor use is not likely to be fruitful as a result of the importance of cooperation among various growth factors. Multiple growth-factor provision by platelet concentrate is promising but limited in the area treatable by the volume of purified platelet concentrate. Noninflammatory dextrose appears to provide clinical benefit in both joint and ligament applications, and it is quite inexpensive. Inflammatory proliferant injection should be more potent than noninflammatory dextrose injection due to the multiplication effects of stimulating the inflammatory cascade. However, the occasional truly inflammatory process may be flared by such inflammatory proliferant solutions. Many studies have been performed to address growth stimulation and have covered all of the described approaches, and many more are desired. The biggest forces driving prolotherapy/RIT toward common usage are its low cost, its ability to actually tighten loose connective tissue, its promising effects on joints, its potential for widespread use in athletics to truly repair overuse injuries and partial tears, and its ability to objectively demonstrate radiographic healing with the increasing use of musculoskeletal ultrasound. It is likely that this will be the century for RIT in sports medicine. Although methods for prolotherapy performance are not the intent of this chapter, **Boxes 50.1 and 50.2** present indications, contraindications, pitfalls, and complications for the interested reader. A recommended text is by Hackett and colleagues,<sup>69</sup> and recent chapters addressing technique are found in *Pain Procedures in Clinical Practice*<sup>70</sup> and *Waldman's Pain Management*.<sup>71</sup>

### Box 50.1: Indications and Contraindications for Regenerative Injection Therapy

#### Indications

1. Pain from chronic sprain or strain impairing athletic performance
2. Connective tissue laxity impairing athletic performance (i.e., shoulder capsular laxity, wrist laxity, anterior cruciate ligament laxity, repetitive ankle inversion tendency)
3. Pain from career sport or activity impairing rest and quality of life

#### Contraindications

1. Potential local infection
2. Allergies (i.e., to local anesthetics if they are used or to shellfish if sodium morrhuate is used); phenol is used digestively and can have no allergy; corn allergy does not appear to be an issue or very rarely (dextrose is made from corn)
3. Local inflammatory process: noninflammatory proliferants would be suggested, potentially after deinflammation with steroid
4. Injection of a prosthetic joint (on principle as a result of increased morbidity in the event of a rare infection); injection around a prosthetic joint as a result of external joint pain sources may be necessary
5. Patient on anticoagulation with an elevated international normalized ratio (it is preferable to have coumadin held before injection similar to other injection procedures); intraspinal hematomas have never been reported but hemarthrosis and hematomas have been either in those with an elevated international normalized ratio or in those taking Lovenox

### Box 50.2: Pitfalls and Complications of Regenerative Injection Therapy

#### Needling Risks (Depending on the Portion of the Body Being Treated)

1. Septic joint: This appears to be similar to steroid injection risk at a rate of 1 in 10,000 to 1 in 40,000 for intra-articular injections.
2. Spinal headache: This is estimated to occur in 1 in 300 low back procedures with lumbosacral junction treatment.
3. Peripheral nerve contact: As a result of the ubiquitous presence of small nerve branches and the occasional contact of larger nerve branches, nerve irritation will occur rarely with treatment. Burning pain reactions are typical, lasting from days to several months.
4. Pneumothorax: This is estimated to occur in about 1 in 20,000 needle insertions in the thoracic region.

#### Solution Risks

1. Stiffness and soreness after treatment: Typically this will last from 1 to 3 days but will occasionally last longer. It is important to have patient contact the physician if flare lasts for more than 10 days because this can be counterproductive in patients with chronic pain.
2. Allergy: Any physician performing injection should prepare for such a reaction and check, in particular, for shellfish allergy before administering sodium morrhuate.
3. Chemical arachnoiditis: This appears to occur with midline injection only of stronger proliferants such as phenol and when boluses in the midline exceed 0.5% or the concentration of phenol exceeds 1.25%. However, this is rare and almost always temporary. Nevertheless, paraspinal injections anywhere near the neural foramina should be with a lesser solution or with small doses and a careful emphasis on concentration limits.

## CONCLUSION

Suboptimal healing may lead to elimination of symptoms and return to full sport. However, suboptimal tissue leaves the athlete with a decrease in tensile strength of the damaged tissue or relative laxity with stretch of fixed length nerve endings. These effects increase susceptibility of the athlete to repetitive injury or rupture, can reflexly inhibit full performance, and create a regional stiffness, even without associated pain. All these are threats to a full and enjoyable career for the elite athlete and can increase the potential for chronic pain after retirement. Much remains to be discovered about stimulating regeneration and blocking degeneration after acute or chronic sports injuries. However, current agents appear capable of restoring connective tissue organization, as seen by ultrasonographic confirmation. The choice of agents will depend on such factors as speed of healing needed, cost efficacy, and the stage of the season.

Education on the basic science of connective tissue injuries and training on how to choose and apply the most cost-effective method of regenerative injection therapy will best be achieved in the context of routine physical medicine and rehabilitation training. Ultrasonographic documentation of lesion reversal may ultimately be used to monitor healing efficacy in this age of evidence-based medicine.

## REFERENCES

1. Wang JH: Mechanobiology of tendon. *J Biomech* 2006;39:1563-1582.
2. Kirkendall DT, Garrett WE: Function and biomechanics of tendons. *Scand J Med Sci Sports* 1997;7:62-66.
3. Woo SL, Gomez MA, Amiel D, et al: The effects of exercise on the biomechanical and biochemical properties of swine digital flexor tendons. *J Biomech Eng* 1981;103:51-56.
4. Soslowky LJ, Thomopoulos S, Tun S, et al: Overuse activity injures the supraspinatus tendon in an animal model: a histologic and biomechanical study. *J Shoulder Elbow Surg* 2000;9:79-84.
5. Kjaer M: Role of extracellular matrix in adaptation of tendon and skeletal muscle to mechanical loading. *Physiol Rev* 2004;84:649-698.
6. Young JS, Kumta SM, Maffulli N: Achilles tendon rupture and tendinopathy: management of complications. *Foot Ankle Clin* 2005;10:371-382.
7. Zernicke RF, Garhammer J, Jobe FW: Human patellar-tendon rupture. *J Bone Joint Surg Am* 1977;59:179-183.
8. Stanish WD, Rubinovich RM, Curwin S: Eccentric exercise in chronic tendinitis. *Clin Orthop Relat Res* 1986;208:65-68.
9. Kannus P, Jozsa L, Natri A, Jarvinen M: Effects of training, immobilization and remobilization on tendons. *Scand J Med Sci Sports* 1997;7:67-71.
10. Warden SJ: Cyclo-oxygenase-2 inhibitors: beneficial or detrimental for athletes with acute musculoskeletal injuries? *Sports Med* 2005;35(4):271-283.
11. Saltzman CL, Tearse DS: Achilles tendon injuries. *J Am Acad Ortho Surg* 1998;6:316-325.
12. Marsolais D, Cote CH, Frenette J: Nonsteroidal anti-inflammatory drug reduces neutrophil and macrophage accumulation but does not improve tendon regeneration. *Lab Invest* 2003;83(7):991-999.
13. Marsolais D, Frenette J: Inflammation and tendon healing. *Med Sci* 2005;21(2):181-186.
14. Sun R, Gimbel HV, Liu S, et al: Effect of diclofenac sodium and dexamethasone on cultured human Tenon's capsule fibroblasts. *Ophthalmic Surg Lasers* 1999;30(5):382-388.
15. Elder CL, Dahners LE, Weinhold PS: A cyclooxygenase-inhibitor impairs ligament healing in the rat. *Am J Sports Med* 2001;29(6):801-810.
16. Riley GP, Cox M, Harrall RL, et al: Inhibition of tendon cell proliferation and matrix glycosaminoglycan synthesis by non-steroidal anti-inflammatory drugs in vitro. *J Hand Surg* 2001;26(3):224-228.
17. Dahners LE, Mullis BH: Effects of nonsteroidal anti-inflammatory drugs on bone formation and soft-tissue healing. *J Am Acad Orthop Surg* 2004;12(3):139-143.
18. Paoloni JA, Orchard JW: The use of therapeutic medications for soft-tissue injuries in sports medicine. *Med J Aust* 2005;183(7):384-388.
19. Cohen DB, Kawamura S, Ehteshami J, et al: Indomethacin and celecoxib impair rotator cuff tendon-to-bone healing. *Am J Sports Med* 2006;34(3):362-369.
20. Kennedy J, Willis RB: The effects of local steroid injections on tendons: a biomechanical and microscopic correlative study. *Am J Sports Med* 1976;4:11-21.
21. Nirschl RP: Elbow tendinosis/tennis elbow. *Clin Sports Med* 1992;11(4):851-870.
22. Reeves KD: Technique of prolotherapy. In Lennard TA (ed): *Physiatric Procedures in Clinical Practice*. Philadelphia, Hanley and Belfus, 1995, pp 57-70.
23. Topol GA, Reeves KD, Hassanein K: Efficacy of dextrose prolotherapy in elite male kicking-sport athletes with chronic groin pain. *Arch Phys Med Rehabil* 2005;86(4):697-702.
24. Price S, Pepper JR, Jaggard SI: Recombinant human erythropoietin use in a critically ill Jehovah's witness after cardiac surgery. *Anesth Analg* 2005;101(2):325-327.
25. Wang JH, Losifidis MI, Fu FH: Biomechanical basis for tendinopathy. *Clin Orthop Relat Res* 2006;443:320-322.
26. Molloy T, Wang Y, Murrell G: The roles of growth factors in tendon and ligament healing. *Sports Med* 2003;33:381-394.
27. Dahlgren LA, van der Meulen MC, Bertram JE, et al: Insulin-like growth factor-1 improves cellular and molecular aspects of healing in a collagenase-induced model of flexor tendinitis. *J Orthop Res* 2003;20:910-919.
28. Aspenberg P, Forslund C: Bone morphogenetic proteins and tendon repair. *Scand J Med Sci Sports* 2000;10:372-375.
29. Fu SC, Wong YP, Chan BP, et al: The roles of bone morphogenetic protein (BMP) 12 in stimulating the proliferation and matrix production of human patellar tendon fibroblasts. *Life Sci* 2003;72:2965-2974.
30. Forslund C, Aspenberg P: Improved healing of transected rabbit Achilles tendon after a single injection of cartilage-derived morphogenetic protein-2. *Am J Sports Med* 2003;31:555-559.
31. Kashiwagi K, Mochizuki Y, Yasunaga Y, et al: Effects of transforming growth factor-beta 1 on the early stages of healing of the Achilles tendon in a rat model. *Scand J Plast Reconstr Surg Hand Surg* 2004;38(4):193-197.
32. Kurtz CA, Loebig TG, Anderson DD, et al: Insulin-like growth factor I accelerates functional recovery from Achilles tendon injury in a rat model. *Am J Sports Med* 1999;27:363-369.
33. Tsubone T, Moran SL, Amadio PC, et al: Expression of growth factors in canine flexor tendon after laceration in vivo. *Ann Plast Surg* 2004;53(4):393-397.
34. Thomopoulos S, Harwood FL, Silva MJ, et al: Effect of several growth factors on canine flexor tendon fibroblast proliferation and collagen synthesis in vitro. *J Hand Surg* 2005;30(3):441-447.
35. Anitua E, Andia I, Sanchez M, et al: Autologous preparations rich in growth factors promote proliferation and induce VEGF and HGF production by human tendon cells in culture. *J Orthop Res* 2005;23(2):281-286.



36. Aspenberg P, Virchenko O: Platelet concentrate injection improves Achilles tendon repair in rats. *Acta Orthop Scand* 2004;75(1):93-99.
37. Taylor MA, Norman TL, Clovis NB, et al: The response of rabbit patellar tendons after autologous blood injection. *Med Sci Sports Exerc* 2002;34(1):70-73.
38. Edwards SG, Calandruccio JH: Autologous blood injections for refractory lateral epicondylitis. *J Hand Surg* 2003;28A(2):272-278.
39. Di Paolo S, Gesualdo L, Ranieri E, et al: High glucose concentration induces the overexpression of transforming growth factor-beta through the activation of a platelet-derived growth factor loop in human mesangial cells. *Am J Pathol* 1996;149(6):2095-2106.
40. Oh JH, Ha H, Yu MR, et al: Sequential effects of high glucose on mesangial cell transforming growth factor-beta 1 and fibronectin synthesis. *Kidney Int* 1998;54(6):1872-1878.
41. Murphy M, Godson C, Cannon S, et al: Suppression subtractive hybridization identifies high glucose levels as a stimulus for expression of connective tissue growth factor and other genes in human mesangial cells. *J Biol Chem* 1999;274(9):5830-5834.
42. Fukuda K, Kawata S, Inui Y, et al: High concentration of glucose increases mitogenic responsiveness to heparin-binding epidermal growth factor-like growth factor in rat vascular smooth muscle cells. *Arterioscler Thromb Vasc Biol* 1997;17(10):1962-1968.
43. Ohgi S, Johnson PW: Glucose modulates growth of gingival fibroblasts and periodontal ligament cells: correlation with expression of basic fibroblast growth factor. *J Periodontol Res* 1996;31(8):579-588.
44. Pugliese G, Pricci F, Locuratolo N, et al: Increased activity of the insulin-like growth factor system in mesangial cells cultured in high glucose conditions. Relation to glucose-enhanced extracellular matrix production. *Diabetologia* 1996;39(7):775-784.
45. Woo SL, Hildebrand K, Watanabe N, et al: Tissue engineering of ligament and tendon healing. *Clin Orthop Relat Res* 1999;367S:312-314.
46. Jones SC, Saunders HJ, Qi W, et al: Intermittent high glucose enhances cell growth and collagen synthesis in cultured human tubulointerstitial cells. *Diabetologia* 1999;42(9):1113-1119.
47. Reeves KD, Hassanein K: Long term effects of dextrose prolotherapy for anterior cruciate ligament laxity: a prospective and consecutive patient study. *Altern Ther Health Med* 2003;9(3):58-62.
48. Reeves KD, Hassanein K: Randomized prospective double-blind placebo-controlled study of dextrose prolotherapy for knee osteoarthritis with or without ACL laxity. *Altern Ther Health Med* 2000;6(2):68-80.
49. Reeves KD, Hassanein K: Randomized prospective placebo controlled double blind study of dextrose prolotherapy for osteoarthritic thumbs and finger (DIP, PIP and trapeziometacarpal) joints: evidence of clinical efficacy. *J Altern Complement Med* 2000;6(4):311-320.
50. Dechow E, Davies RK, Carr AJ, et al: A randomized, double-blind, placebo-controlled trial of sclerosing injections in patients with chronic low back pain. *Rheumatology* 1999;38(12):1255-1259.
51. Altay T, Gunal I, Ozturk H: Local injection treatment for lateral epicondylitis. *Clin Orthop* 2002;398:127-130.
52. Hackett GS. *Ligament and Tendon Relaxation Treated by Prolotherapy*, 3rd ed. Springfield, IL, Charles C. Thomas, 1956.
53. Liu YK, Tipton CM, Matthes RD, et al: An in-situ study of the influence of a sclerosing solution in rabbit medial collateral ligaments and its junction strength. *Connect Tissue Res* 1983;11:95-102.
54. Maynard JA: Morphological and biochemical effects of sodium morrhuate on tendons. *J Orthop Res* 1985;3(2):236-248.
55. Aneja A, Karas SG, Weinhold PS, et al: Suture plication, thermal shrinkage, and sclerosing agents: Effects on rat patellar tendon length and biomechanical strength. *Am J Sports Med* 2005;33(11):1729-1734.
56. Ongley MJ, Dorman TA, Eek BC, et al: Ligament instability of knees: a new approach to treatment. *Man Med* 1988;3:152-154.
57. Bahme BB: Observations on the treatment of hypermobile joints by injection. *J Am Osteopath Assoc* 1945;45:101-109.
58. Blaschke JA: Conservative management of intervertebral disc injuries. *J Okla State Med Assoc* 1961;54:494-501.
59. Myers A: Prolotherapy treatment of low back pain and sciatica. *Bull Hosp Joint Dis* 1961;22:48-55.
60. Peterson TH: Injection treatment for back pain. *Am J Orthop Surg* 1963;246:320-321.
61. Schwartz RG, Segedy N: Prolotherapy: a literature review and retrospective study. *J Neurol Orthop Med Surg* 1991;12:220-223.
62. Hackett GS, Huang TC: Prolotherapy for headache. *Headache* 1962;2:20-28.
63. Kayfetz DO, Blumenthal LS, Hackett GS, et al: Whiplash injury and other ligamentous headache: its management with prolotherapy. *Headache* 1963;3:21-28.
64. Ongley MJ, Klein RG, Dorman TA, et al: A new approach to the treatment of chronic low back pain. *Lancet* 1987;2:143-146.
65. Klein RG, Bjorn CE, DeLong B, et al: A randomized double-blind trial of dextrose-glycerine-phenol injections for chronic low back pain. *J Spinal Disord* 1993;6:23-33.
66. Yelland MJ, Glasziou PP, Bogduk N, et al: Prolotherapy injections, saline injections, and exercises for chronic low-back pain: a randomized trial. *Spine* 2004;29(1):9-16.
67. Rabago D, Best TM, Beamsley M, Patterson J: A systematic review of prolotherapy for chronic musculoskeletal pain. *Clin J Sport Med* 2005;15(5):376-380.
68. Lazzara MA: The non-surgical repair of a complete Achilles tendon rupture by prolotherapy: biological reconstruction. A case report. *J Orthop Med* 2005;27(3):128-132.
69. Hackett GS, Hemwall GA, Montgomery GA. In Hemwall Gustav A (ed): *Ligament and Tendon Relaxation Treated by Prolotherapy*, 5th ed. IL, Oak Park, 1992.
70. Reeves KD: Prolotherapy: basic science, clinical studies, and technique. In Lennard TA (ed): *Pain Procedures in Clinical Practice*, 2nd ed. Philadelphia, Hanley and Belfus, 2000, pp 172-190.
71. Reeves KD: Prolotherapy: injection of growth factors or growth factor production stimulants to grow normal cells or tissue. In Waldman SD (ed): *Pain Management*. Philadelphia, Elsevier, 2006, pp 1106-1127.