

## WONDER WHY?

# Neural Prolotherapy

Adam D. Weglein, DO, DABMA

## ABSTRACT

*There are many new developments in the world of regenerative Orthopedic Medicine. One innovative treatment option is called Neural Prolotherapy. Traditional Prolotherapy has focused on ligament-tendon healing, and has shown to be a powerful treatment modality. With Neural Prolotherapy, however we shift our focus to the subcutaneous nerves as a source of pathology. These subcutaneous nerves in a pathologic state can lead to neurogenic inflammation and pain. We introduce and explore the use of low dose dextrose Prolotherapy in the treatment of neurogenic inflammatory pain. Neural Prolotherapy is indeed a fantastic treatment option that has the potential to further our healing profession.*

*Journal of Prolotherapy. 2011;3(2):639-643.*

**KEYWORDS:** Neural Prolotherapy, Neurofascial Prolotherapy, neurogenic inflammation.

## PERSONAL BACKGROUND

**P**rolotherapy or Proliferation Therapy stimulates regeneration and repair of injured tissue with the use of dextrose and other agents. I was introduced to Prolotherapy during my Sports Medicine fellowship at South Pointe- Cleveland Clinic by Dr. Zenos Vangelos (Program Director Sports Medicine Fellowship, SP-Cleveland Clinic). I was first introduced to the concept of Neural Prolotherapy by Dr. Dean Reeves. I subsequently traveled to Ferrara, Italy to obtain training from Dr. John Lyftogt in Neural Prolotherapy.

## BRIEF HISTORY OF NEURAL PROLOTHERAPY

Neural Prolotherapy also called Neurofascial Prolotherapy (NPT) is one of the newest advances in Regenerative Orthopedic Medicine. Neural Prolotherapy is not to be confused with traditional "German" Neural injection therapy. German Neural therapy is a great treatment option using procaine to treat interference fields and scars.<sup>13</sup> I regularly treat my patients with scars using this German Neural therapy technique.

Neural Prolotherapy (NPT) was primarily born out of clinical observations and involves the treatment of neurogenic inflammation. Neural Prolotherapy has its roots dating back to 1989 with Dr. Paul Pybus and Dr. Roger Wyburn-Mason, in their book "Intraneural Injections for Rheumatoid Arthritis and Osteoarthritis." In the book Dr. Pybus explains the concept of neurogenic inflammation as it relates to osteoarthritis.<sup>14</sup>

## PATHOLOGY OF NEUROGENIC INFLAMMATION

The pathology of neurogenic inflammation is well established.<sup>1, 2, 16</sup> Ligaments, tendons and joints have TRPV1-sensitive C pain fiber innervation. Dr. Pybus explains that the C pain fibers transmit the "deep pain" often seen with osteoarthritis.<sup>14</sup> "When these C pain fibers are irritated anywhere along their length they will transmit ectopic impulses in both forward (prodromic) and reverse (antidromic) direction."<sup>14</sup> The forward direction of the nerve signal will cause pain perception as the signal travels through the posterior root ganglia up to the brain. You will also have a local reflex action from the spinal cord ventral horn cells out to the muscle fibers, which will cause a reflex muscle spasm.<sup>14</sup> The reverse (antidromic) signal will travel to the blood vessels where substance P is released causing swelling and pain. The nerves themselves also have a nerve supply called the Nervi Nervorum (NN).<sup>2</sup> In a pathological state, the NN can release substance P (Sub P) and Calcitonin Gene Related Peptide (CGRP) onto these C pain fibers.<sup>11</sup> Sub P and CGRP are known to cause pain, swelling of the nerve and surrounding tissue.<sup>7</sup>

Dr. Pybus treated this above neurogenic inflammation with lidocaine and steroid injections. Dr. John Lyftogt and Dr. Dean Reeves expanded on Dr. Pybus' work adding the dextrose Prolotherapy concept. Dr. Lyftogt noticed that these same nerves responded even better to a low dose dextrose injection. He will be expanding on this further in his upcoming book. Dr. Lyftogt discussed in his recent Neural Prolotherapy meeting that "Cutaneous nerves pass through many fascial layers on their way to the spine. When there is neurogenic swelling at the Fascial Penetration Zone, a Chronic Constriction Injury (CCI) occurs. The CCI points will inhibit flow of Nerve Growth Factor (NGF).<sup>8, 7</sup> Proper flow of NGF is essential for nerve health and repair."<sup>3</sup> (See Figure 1.)

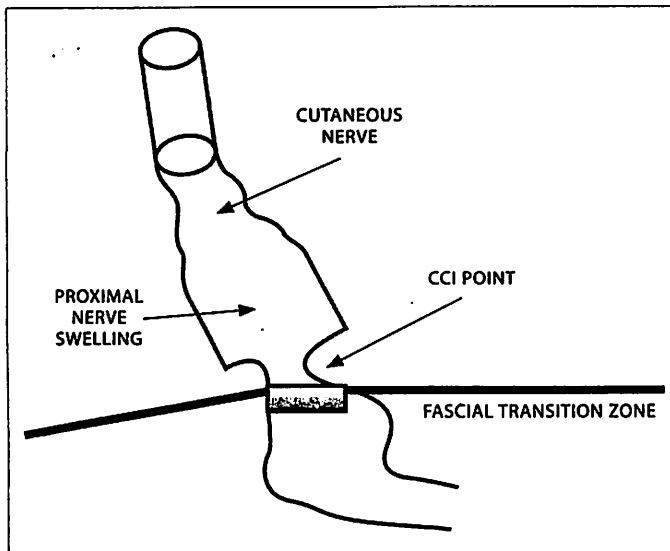


Figure 1. Cutaneous nerve chronic constriction injury.

There are two major ways that the fascial penetration point can affect a nerve. Trauma to a nerve will cause edema to travel proximal and distal to the injury. When this swelling reaches the fascial penetration points this can cause a self-strangulation of the nerve and decrease nerve growth factor flow.<sup>16, 17</sup> Morton's neuroma is a clinical example of this.<sup>17</sup> Dr. Pybus has also suggested that a change in fascial tension from repetitive muscle dysfunction can also cause a CCI point.<sup>15, 17</sup> Another critical concept in NPT is what is called Bystander disease.<sup>9, 17</sup> Bystander disease helps explain how superficial nerve pathology can affect deeper anatomic structures.<sup>9</sup> This is based on Hilton's law. Hilton's law states: the nerve supplying a joint also supplies both the muscles that move the joint and the skin covering the articular insertion of those muscles.<sup>9</sup> An example: The musculocutaneous nerve supplies the elbow with pain and proprioception as it is the nerve supply to the biceps brachii and brachialis muscles, as well as the skin close to the insertion of these muscles.<sup>17</sup> Hilton's Law arises as a result of the embryological development of humans. This concept of Hilton's law coupled with the idea of anterograde and retrograde axonal flow of neurodegenerative peptides,<sup>17</sup> can help explain the wide reaching affects of NPT on pain control.

#### TREATING NEUROGENIC INFLAMMATION

Clinical observation has shown that a 5% dextrose solution with sterile water will give immediate analgesia. In my experience, this pain control will last from 4 hours to 3 weeks. The proposed mechanism is again a dextrose mediated inhibition of the neurogenic inflammation.

Glucose responsive nerves have been demonstrated throughout the nervous system.<sup>4, 5, 6</sup> One proposed mechanism of action suggests that dextrose binds to pre synaptic calcium channels and inhibits the release of substance P and CGRP, thereby decreasing neurogenic inflammation. This allows normal flow of nerve growth factor and subsequent nerve repair and decreased pain.<sup>7</sup>

Dr. Lyftogt has studied the use of a wide range of dextrose, lidocaine, and procaine concentrations. At this point in time, he is using 5% dextrose in sterile water solution (1cc of dextrose 50 in 9cc sterile water). No lidocaine is used. NPT is given just under the skin close to subcutaneous nerves at weekly intervals.

#### RESEARCH

Dr. Lyftogt's early research focused on the treatment of Achilles tendons. He has treated over 300 Achilles tendons with a success rate of more than 90%. Dr. Lyftogt has published six level 4 studies in the *Australian Journal of Musculoskeletal Medicine* since 2005. He has studied the shoulder, ankle, back, elbow, and hip. His 2 year follow up shows a 80-100% success rate.<sup>10, 11, 12</sup>

#### PERSONAL EXPERIENCE WITH NEURAL PROLOTHERAPY

I have been using Neural Prolotherapy in my practice for the past year with outstanding results. I find myself often using NPT as my first treatment option, followed by traditional Prolotherapy and Platelet Rich Plasma as needed. My approach is to treat from the superficial to deep tissues. Along with my complete history and physical exam, I now check for swollen and painful peripheral nerves. If the subcutaneous nerves are swollen or painful on examination, this is an indication to treat with NPT.

#### CASE EXAMPLES

Aforementioned, I now use NPT as a first line treatment on most patients. In the photos, the circles represent the chronic constriction points (CCI) of the superficial nerves. If the CCI points are tender to palpation, they need to be treated to have a successful outcome.

#### CASE 1: SHOULDER ROTATOR CUFF TEAR AND SUPRACLAVICULAR NEUROGENIC INFLAMMATION

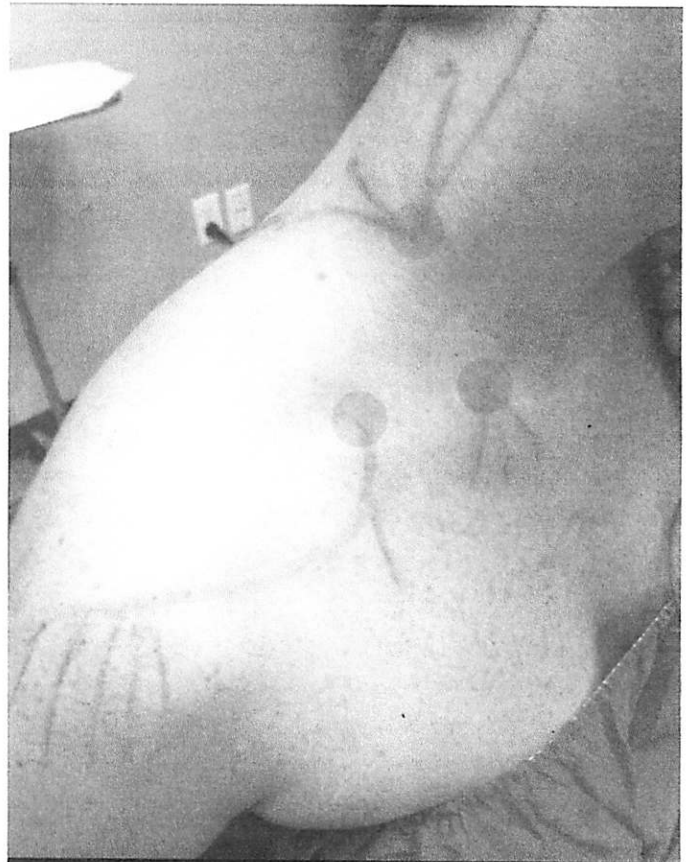Mr. VF is a 59-year-old male with a complaint of right shoulder pain for the past 7 months. The patient had an MRI of his right shoulder that showed an articular

supraspinatus partial tear 11mm. I used Platelet Rich Plasma (PRP) along with Prolotherapy, 15% dextrose and lidocaine solution, to treat the supraspinatus tendon under ultrasound guidance on 7/26/2010. The patient underwent my post PRP-Prolotherapy physical therapy protocol for 6 weeks. This is a week-by-week incremental increase in physical therapy to enhance the healing benefit of PRP.

On Mr. VF's follow up visit with me on 9/13/10 he reported 85% improvement in shoulder pain and function. His physical exam was full passive range of motion and active range of motion. He did have pain in his shoulder with golf swinging and on palpation over the subcutaneous shoulder supraclavicular nerve. Due to the fact that the patient had pain over the path of the supraclavicular nerve, I decided to treat this nerve with Neural Prolotherapy, 5% dextrose in sterile water. (See Figure 2.) He had 4 injections done at that visit along the supraclavicular nerve. The patient had immediate complete pain control, which lasted for 3 days. He followed up at weekly intervals. Each week he had decreased pain and required fewer injections. A total of 3 weeks (3 treatments) of Neural Prolotherapy were done. The patient had complete pain relief in his shoulder and was able to continue golfing pain free.

#### CASE 2: LOWER BACK PAIN WITH SUPERIOR CLUNEAL NEUROGENIC INFLAMMATION

Mr. GH is a 50-year-old with a history of lumbar pain for the past 26 years. His pain was located in his lumbar L5 paraspinous area on the left, superficial to the facet area. He had some occasional radicular symptoms down his left leg, however not at the time of presentation to my clinic. He had tried chiropractic treatments, physical therapy. He had an MRI that showed L4/L5 hypertrophy of facet joints. L5/S1 broad 5mm posterior disc protrusion and no thecal sac effacement. In addition, his MRI stated left sided facet hypertrophy moderate and left sided foraminal narrowing. On physical exam the patient had pain on superficial exam of the L4, L5 paraspinous muscles (ventral rami nerves), along with pain on superficial exam of the L1, L2 superior cluneal nerves. (See Figure 3.) I decided to use Neural Prolotherapy as a treatment based on pain over these superficial nerves. The patient underwent 5 weekly treatments of Neural Prolotherapy. The lumbar L4 and L5 left sided near ventral rami injections were done with a vertical 1/2-inch, 27G needle. The left sided superior cluneal L1, L2 were also injected. All injections were done with 5% dextrose in sterile water, 0.5cc injected

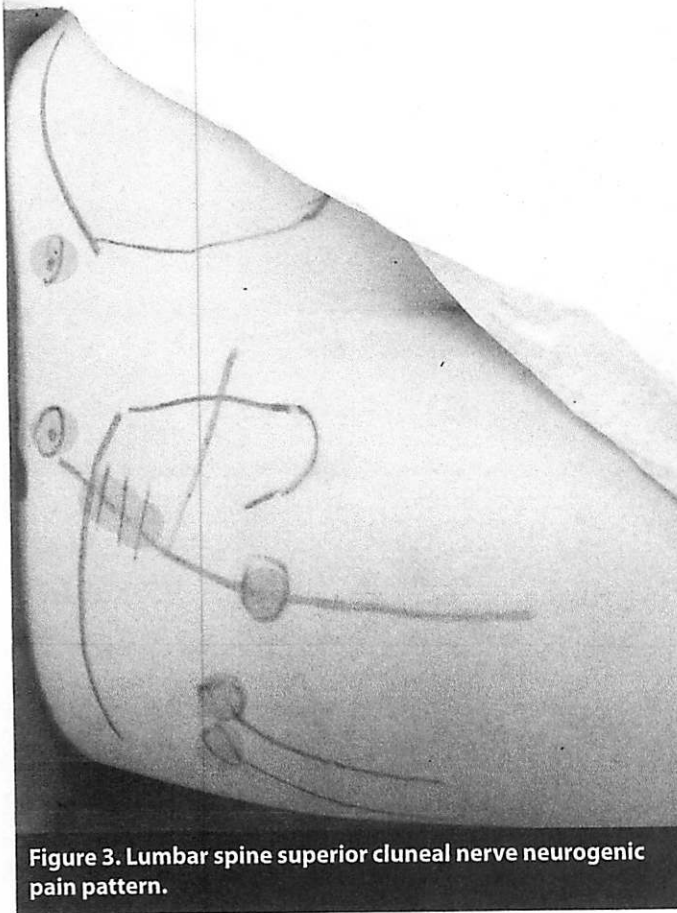


**Figure 2. Shoulder supraclavicular nerve neurogenic pain pattern.** Neural Prolotherapy eliminates the neurogenic inflammatory component of pain.

subcutaneous per site. At his 12-week follow up he was completely free of pain.

#### CASE 3: KNEE PAIN WITH SAPHENOUS NEUROGENIC INFLAMMATION

Mr. MW is a 57-year-old who had left knee pain for 3 months. His MRI of the left knee showed tricompartment osteoarthritis, medial diffuse degenerative fraying of meniscus, lateral degenerative fraying of meniscus. The patient had most of his pain initially within the knee joint, as morning stiffness. We started treatment for osteoarthritis with intraarticular hyaluronic acid injections (Euflexxa). This gave him only a minor benefit. We proceeded to do a course of Prolotherapy. He had 3 treatments of Prolotherapy. At each treatment, he received Prolotherapy intraarticular, to his medical collateral ligament, and coronary ligaments along his medial meniscus. This provided benefit. To further healing, at his next visit, we proceeded to do Platelet Rich Plasma and Prolotherapy to the coronary medial ligaments, MCL and intraarticular.

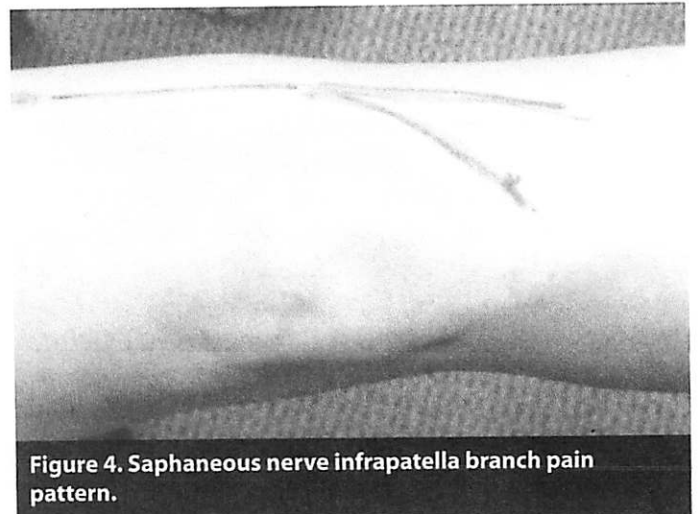

**Figure 3. Lumbar spine superior cluneal nerve neurogenic pain pattern.**

With his two month post-PRP follow up he had much improved pain control and no locking or giving out of the knee. He no longer had the deep pain within his knee. He did have superficial pain over the knee saphenous nerve; thus, Neural Prolotherapy was done. He had a total of 4 weekly Neural Prolotherapy treatments to the saphenous nerve. On his follow up he was pain free, had full range of motion, and no further treatment was needed.

#### CASE 4: KNEE PAIN MENISCUS PAIN WITH SAPHENOUS NERVE NEUROGENIC INFLAMMATION

Mr. B O'M is a 46-year-old male with left knee pain for the past 6 months, after injuring his knee playing golf. His MRI showed medial meniscus tear. The patient had undergone two arthroscopic surgeries to try and repair the meniscus tear. On physical exam the patient had pain along his medial saphenous nerve on the left knee. Due to the fact that the patient had pain along the saphenous nerve on physical exam, we started treatment with Neural Prolotherapy to this area. (See Figure 4.) He had a total of 4 weekly treatments of Neural Prolotherapy. The patient



**Figure 4. Saphenous nerve infrapatella branch pain pattern.**

reported that the superficial pain over the medial joint line at the location of the saphenous nerve was no longer present, but that there was still a deeper medial knee pain. We proceeded to do traditional Prolotherapy and Platelet Rich Plasma intraarticular and along medial coronary ligaments, which gave him complete pain relief.

I hope these cases help demonstrate the potential use of NPT in Orthopedic Medicine.

As in all forms of medicine, the closer we are to establishing the etiology of disease, the better our treatment outcomes are. When we consider the complexity of musculoskeletal derived pain, we need to address the etiology of pain at its root cause. There are many pain generators such as bone, ligament, tendon, fascial, muscle and nerve. Traditional Prolotherapy and Platelet Rich Plasma have demonstrated their structural healing ability. Now with the use of Neural Prolotherapy we can address the pathology of neurogenic inflammation bringing yet another level to our healing profession. ■

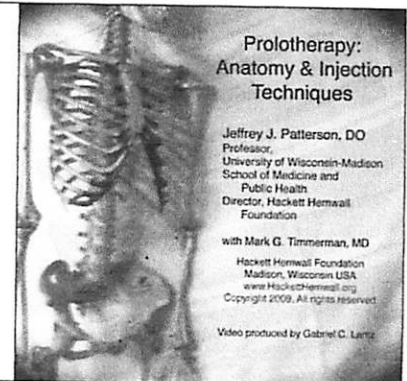
REFERENCES:

1. Geppetti, et al. *Neurogenic Inflammation*. Boca Raton: Edited CRC Press; 1996. Chapter 5, Summary; p.53-63.
2. Marshall J. Nerve stretching for the relief or cure of pain. *The Lancet*. 1883;2:1029-36.
3. Levi-Montalcini R, et al. Developmental neurobiology and the natural history of nerve growth factor. *Ann. Rev. Neurosc.* 1982; 5:341-62.
4. Fujita S, et al. Hypoglycaemic detection at the portal vein is mediated by capsaicin-sensitive primary sensory neurons. *Am J Physiol Endocrinol Metab*. 293: E96-E101, 2007. First published March 20, 2007.
5. Gonzalez JA, et al. Dissociation between sensing and metabolism of glucose in sugar sensing neurons. *J Physiol*. 2009;587:41-48.
6. Harrison D, et al. Efficacy of sweet solutions for analgesia in infants between and 12 months of age: a systematic review. *Arch Dis Child*. 2010;95(6):406-13.
7. Lyftogt J. The Hackett Hemwall Foundation and the Italian Society for Prolotherapy sponsored. "Neural Prolotherapy Workshop meeting." 2010 Ferrara, Italy.
8. Bennett GJ, et al. A peripheral mononeuropathy in rat that produces disorders of pain sensation like those seen in man. *Pain*. 1988;33(1):87-107.
9. Hilton J. On rest and Pain. In Jacobsen WHA(ed): *On Rest and Pain*, 2nd edition, New York: William Wood & company, 1879.
10. Lyftogt JA. Prolotherapy for recalcitrant lumbago. *Aust Musculoskeletal Med*. 2008;13(1):18-20.
11. Lyftogt J. Subcutaneous prolotherapy treatment of refractory knee, shoulder and lateral elbow pain. *Aust Musculoskeletal Med*. 2007;12(2):110-12.
12. Lyftogt J. Subcutaneous prolotherapy for achilles tendinopathy: the best solution? *Aust Musculoskeletal Med*. 2007;12(2):107-109.
13. Kidd R. *Neural Therapy Applied Neurophysiology and other topics*. 1st edition Canada: Custom Printers of Renfrew LTD publishers; 2005. Chapter 3,summary; .p 24-35.
14. Pybus P, et al. Intra-neural injections for rheumatoid arthritis and osteoarthritis. *Arthritis Trust of America*. 1989; p9-22.
15. Bennett GJ, et al. A peripheral mononeuropathy in rat that produces disorders of pain sensation like those seen in man. *Pain*. 1988;33:1685-1690.
16. Jancso N, et al. Direct evidence for neurogenic inflammation and its prevention by denervation and by pretreatment with capsaicin. *Br J Pharmacol Chemother*. 1967;31:138-151.
17. Reeves KD, et al. Prolotherapy: regenerative injection therapy. In: *Waldman SD pain Management*. Philadelphia; Saunders: 2nd edition. 2011: pp1-11.

PURCHASE THE PROLOTHERAPY INSTRUCTIONAL DVD:

# Prolotherapy: Anatomy & Injection Techniques

By Jeffrey J. Patterson, DO with Mark G. Timmerman, MD



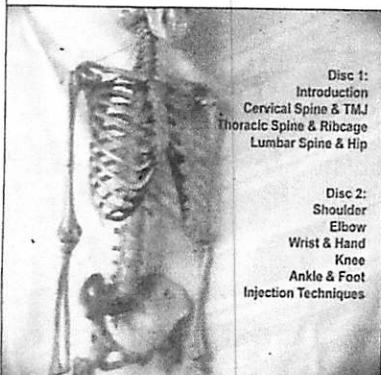
Prolotherapy:  
Anatomy & Injection  
Techniques

Jeffrey J. Patterson, DO  
Professor,  
University of Wisconsin-Madison  
School of Medicine and  
Public Health  
Director, Hackett Hemwall  
Foundation

with Mark G. Timmerman, MD  
Hackett Hemwall Foundation  
Madison, Wisconsin USA  
[www.hacketthemwall.org](http://www.hacketthemwall.org)

Copyright 2009. All rights reserved.

Video produced by Gabriel C. Lema



Disc 1:  
Introduction  
Cervical Spine & TMJ  
Thoracic Spine & Ribcage  
Lumbar Spine & Hip

Disc 2:  
Shoulder  
Elbow  
Wrist & Hand  
Knee  
Ankle & Foot  
Injection Techniques

DVD Set: \$300 + \$7.50 US Shipping = **\$307.50**

Buy online at: [www.hacketthemwall.org](http://www.hacketthemwall.org)

OR

Mail a check in US funds to: Hackett Hemwall Foundation,  
2532 Balden Street, Madison, WI 53713. Include your shipping address.

THE HACKETT HEMWALL FOUNDATION