

STEM CELLS®

Injectable Mesenchymal Stem Cell Therapy for Large Cartilage Defects A Porcine Model

Kevin B.L. Lee, James H.P. Hui, Im Chim Song, Lenny Ardany and Eng Hin Lee
Stem Cells 2007;25;2964-2971; originally published online Jul 26, 2007;
DOI: 10.1634/stemcells.2006-0311

This information is current as of December 3, 2007

The online version of this article, along with updated information and services, is located on the World Wide Web at:

<http://www.StemCells.com/cgi/content/full/25/11/2964>

STEM CELLS®, an international peer-reviewed journal, covers all aspects of stem cell research: embryonic stem cells; tissue-specific stem cells; cancer stem cells; the stem cell niche; stem cell genetics and genomics; translational and clinical research; technology development.

STEM CELLS® is a monthly publication, it has been published continuously since 1983. The Journal is owned, published, and trademarked by AlphaMed Press, 318 Blackwell Street, Suite 260, Durham, North Carolina, 27701. © 2007 by AlphaMed Press, all rights reserved. Print ISSN: 1066-5099. Online ISSN: 1549-4918.

 **AlphaMed Press**

Injectable Mesenchymal Stem Cell Therapy for Large Cartilage Defects—A Porcine Model

KEVIN B.L. LEE, JAMES H.P. HUI, IM CHIM SONG, LENNY ARDANY, ENG HIN LEE

The Department of Orthopaedic Surgery, National University of Singapore, and the Department of Experimental Surgery, Singapore General Hospital, Singapore, Republic of Singapore

Key Words. Cartilage defects • Minimally invasive • Mesenchymal stem cells • Hyaluronic acid • Injectable

ABSTRACT

Current techniques in biological resurfacing of cartilage defects require an open arthrotomy or arthroscopy and involve the direct transplantation of isolated cells and/or scaffolds or whole tissue grafts with chondrogenic potential onto the cartilage defect. Our study investigates the possibility of direct intra-articular injection of mesenchymal stem cells suspended in hyaluronic acid (HA) as an alternative to the much more invasive methods currently available. A partial-thickness (without penetration of the subchondral bone) cartilage defect was created in the medial femoral condyle of an adult minipig. Mesenchymal stem cells from the iliac crest marrow of the same pig harvested in a separate procedure and suspended in 2

milliliters of hylan G-F 20 (Synvisc) were injected intra-articularly after the creation of the defect. This was followed by two more injections of hylan G-F 20 (HA) at weekly intervals. Either saline or HA was injected into the knees of the controls. The pigs were sacrificed at 6 and 12 weeks for morphological and histological analysis. The cell-treated groups showed improved cartilage healing both histologically and morphologically at 6 and 12 weeks compared with both controls. The use of intra-articular injections of mesenchymal stem cells suspended in HA is a viable option for treating large cartilage defects. This would be further explored in clinical trials. *STEM CELLS* 2007;25:2964–2971

Disclosure of potential conflicts of interest is found at the end of this article.

INTRODUCTION

Cartilage injuries are a common clinical problem that, if left untreated, could lead to osteoarthritis. With the ageing population worldwide, this will become one of the leading clinical problems faced by orthopaedic surgeons.

It is well known that the capacity of articular cartilage for repair is limited. Injuries of the articular cartilage that do not penetrate the subchondral bone do not heal and usually progress onto the degeneration of the articular surface. A short-lived response is normally observed, but it fails to provide sufficient cells and matrix to repair even the smaller defects [1–4]. Injuries that penetrate the subchondral bone undergo repair through the formation of fibrous, fibrocartilaginous, or hyaline-like cartilaginous tissues, depending on the species and age of the animal as well as the location and size of the injury [5–8]. These tissues, even those that resemble hyaline cartilage histologically, differ from normal hyaline cartilage both biochemically and biomechanically. After 6 months, degenerative changes appear in these tissues of approximately half of the full-thickness defects [9, 10]. Similarly, the degenerated cartilage seen in osteoarthritis does not usually undergo repair but progressively deteriorates.

Current techniques in biological resurfacing of cartilage defects require an open arthrotomy or arthroscopy and involve the direct transplantation of isolated cells and/or scaffolds or whole tissue grafts with chondrogenic potential onto the cartilage defect. All the above methods are invasive, and none has been shown to be superior to the rest [11].

To date, there has been only one study describing the direct intra-articular injection of stem cells in a goat model of osteoarthritis [12]. This study used an osteoarthritis model that involved excision of the anterior cruciate ligament and the total medial meniscus. The study showed reduced degeneration of the articular cartilage and marked regeneration of medial meniscus in the cell-treated group. Based on this study, we proposed an injectable option using MSCs suspended in hyaluronic acid (HA) for the treatment of large chondral defects in a porcine model, thus combining the regenerative potential of MSCs and the known chondroinductive and chondroprotective properties of hyaluronic acid using a scaffoldless minimally invasive technique. Our aim is to provide a novel idea of injectable MSCs as an alternative solution to the problem of cartilage regeneration.

MATERIALS AND METHODS

Animal Groups

Twenty-seven adult pigs of mean age 1 year old and mean weight 42 kg were randomly assigned to three groups. They were defined according to different therapeutic methods; group 1 was treated with an injection of MSCs and HA, and groups 2 and 3, which were control groups, were injected with HA and saline, respectively. All the animals had a partial thickness chondral defect created in the medial femoral condyle. They were then subjected to the different therapies according to the groups to which they were assigned. In each group, three pigs were sacrificed at 6 weeks from the time of the first injection and six pigs were sacrificed at 12 weeks. The

femoral condyles were isolated for histomorphological analysis. The project was approved by the Institutional Animal Care and Use Committee and conducted in compliance with the National Advisory Committee for Laboratory Animal Research Guidelines.

MSC Isolation and In Vitro Proliferation

The MSCs were harvested from the iliac crest marrow in a separate procedure 3 weeks prior to surgery. Ten milliliters of marrow was aspirated with a needle (Jamshidi Bone Marrow Biopsy/Aspiration Needles 11GA; Cardinal Health, Dublin, Ohio, <http://www.cardinal.com>) into a syringe containing 0.5 ml of heparin. The aspirated sample was centrifuged and rinsed with Hanks' balanced salt solution (HBSS). The pelleted components were resuspended with adequate amounts of complete medium (Dulbecco's modified Eagle's medium [DMEM], fetal bovine serum [FBS], L-glutamine, and sodium pyruvate) before being distributed into a cell culture flask. Complete medium in the cultured flask was replaced every 2 days. After 1 week, nonadherent cells were washed off with phosphate-buffered saline (PBS), and fresh medium was added.

Once passage 0 (P0) cells reached 75% confluency in the seeded flask, the colonies were trypsinized and seeding of P1 cells began. A mean of 7.0 million MSCs with a range of 3.5–10.1 million were obtained at 3 weeks. The P1 cell suspensions were rinsed to remove traces of complete medium. After a final rinse with sterile normal saline, the cells were carefully introduced into a new syringe together with 2 ml of hylan G-F 20 (Synvisc). This was performed under aseptic conditions.

Tripotential Differentiation of MSCs

Adipogenic differentiation was induced by culturing MSCs for 2 weeks in adipogenic medium (DMEM containing 10% FBS, 1 μ M dexamethasone, 0.5 mM isobutylmethylxanthine, 10 μ g/ml insulin, and 100 μ M indomethacin) and assessed using an oil red O stain. Osteogenic differentiation was induced by culturing MSCs for 2 weeks in osteogenic medium (DMEM containing 10% FBS, 100 nM dexamethasone, 10 mM glycerophosphate, and 50 μ M ascorbic acid) and examined for extracellular matrix calcification by alizarin red stain. Chondrogenic differentiation was induced using the micro-mass culture technique. Briefly, 3×10^5 cells were pelleted into a 15-ml horn tube and cultured in chondrogenic medium (DMEM containing 1% FBS, 50 μ g/ml ascorbic acid, 10 ng/ml transforming growth factor- β 1, and 6.25 μ g/ml insulin) for 3 weeks. The pellet was gently overlaid so as not to detach the cells. Chondrogenesis was confirmed by toluidine blue stain [13].

Creation of the Chondral Defect

The animals were induced using intramuscular (IM) ketamine at 15 mg/kg and maintained using 2% inhalational halothane. IM Baytril at 2.5 mg/kg was given preoperatively and for 5 days postoperatively. Tengesic at 0.005 mg/kg was given as postoperative analgesia. The mean weight of the pigs was 42 kg at the initial operation. At the initial operation, a standard medial parapatellar approach was used to expose the knee. A defect was created in the weight-bearing area of the medial femoral condyle using a special tube osteotome with a depth-limiter (Fig. 1A). The base of the defect was smoothed by a surgical scalpel. Care was taken not to breach the subchondral bone, and the calcified layer was left intact. The defect size was 8.5 mm and 1 mm deep, and on average this was 60% of the medial femoral condyle width. Careful hemostasis and a layered closure were performed to ensure a watertight seal, and the pigs were allowed to move freely postoperatively with adequate analgesia given. All of the operations were performed by K.B.L. Lee, an orthopedic surgeon.

Healing of the Chondral Defect

Three separate intra-articular injections were given postoperatively at weekly intervals following the same schedule as the technique of viscosupplementation using HA. The first injection was given a week after the index operation. The study group had an initial injection of MSCs suspended in 2 ml of HA followed by two more injections of HA in the following 2 weeks. The two control groups had three separate weekly injections of either normal saline or HA.

www.StemCells.com

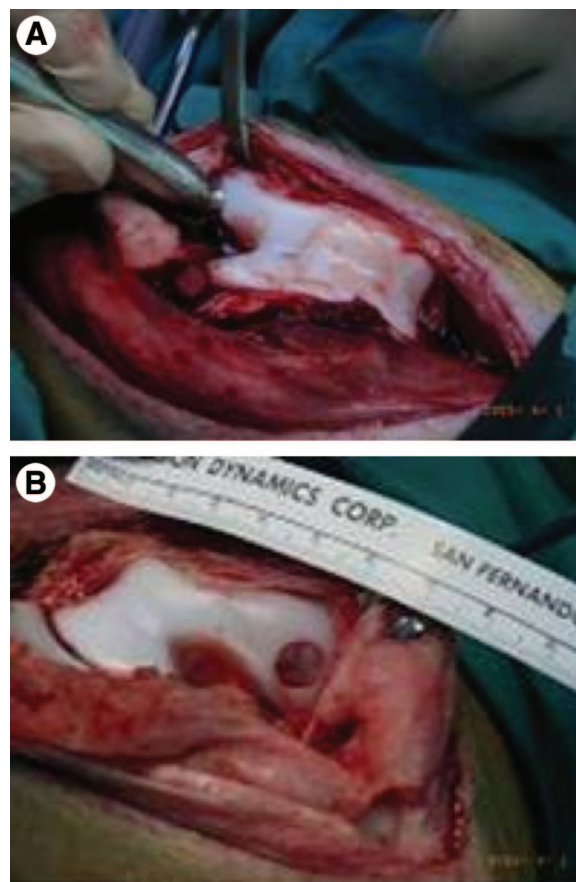


Figure 1. Chondral defect of the medial femoral condyle. (A): Creation of the defect with a tube osteotome. (B): The resultant defect.

Histological Analysis and Immunostaining

In each group, three pigs were sacrificed at 6 weeks from the time of the first injection and six pigs were sacrificed at 12 weeks. The method of euthanasia was i.v. injection of a lethal dose of thiopentone. The specimens were fixed in 10% formalin, decalcified and sectioned longitudinally, and stained with hematoxylin and eosin (cellular architecture), Masson's trichrome (collagen), and Safranin O (cartilage proteoglycan).

Samples of the study group (MSC-treated) at 12 weeks were also prepared for immunohistological staining. Mouse derived monoclonal antibodies against collagen type I (mouse anti-collagen type I monoclonal antibody; Chemicon, Temecula, CA, <http://www.chemicon.com>) and collagen type II (mouse anti-chicken collagen type II monoclonal antibody; Chemicon) were used to detect the collagen distribution in the repair tissue. UltraVision detection system (Lab Vision, Fremont, CA, <http://www.labvision.com>) was used to visualize these antibodies. Immunohistology stains were performed according to the protocol provided in the manual. Briefly, 4- μ m-thick sections were affixed onto glass slides, deparaffinized, rehydrated, and digested with pepsin (Lab Vision) for 20 minutes at 37°C. The slide was then incubated in hydrogen peroxide block solution for 15 minutes, and Ultra V Block solution was applied for 5 minutes at room temperature. Primary antibodies were applied and incubated overnight at 4°C. Biotinylated goat anti-mouse solution and streptavidin peroxidase solution were applied at room temperature for 30 minutes and 45 minutes separately. Afterward, diaminobenzidine was applied to these cells, which were then incubated and monitored under a microscope for the desired stain intensity. All images were taken from the defect-repair region.

In Vivo Tracing of MSCs

To allow in vivo tracing of the injected MSCs, labeling was performed with carboxyfluorescein diacetate succinimidyl ester

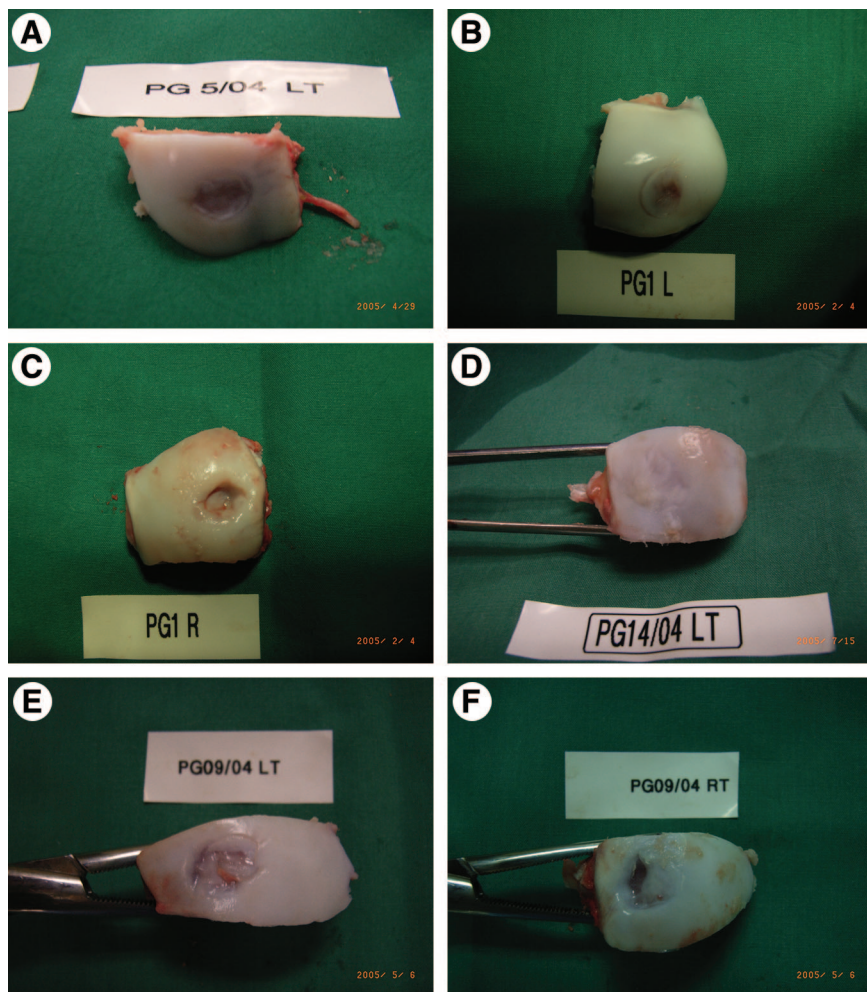


Figure 2. Images of the repaired chondral defects. (A): Gross morphological assessment at 6 weeks showing almost complete healing of the defect with MSCs + hyaluronic acid (HA). (B): Gross morphological assessment at 6 weeks showing partial healing of the defect with HA. (C): Gross morphological assessment at 6 weeks showing no healing of the defect with saline. (D): Gross morphological assessment at 12 weeks showing almost complete healing of the defect with MSCs + HA. (E): Gross morphological assessment at 12 weeks showing partial healing of the defect with HA. (F): Gross morphological assessment at 12 weeks showing no healing of the defect with saline.

(CFDA-SE; Vybrant CFDA SE Cell Tracer Kit [V-12883]; Molecular Probes, Eugene, OR, <http://probes.invitrogen.com>). CFDA-SE was dissolved in dimethylsulfoxide, and this mixture was diluted with prewarmed PBS to obtain a working concentration of $5.0 \mu\text{M}$. The *in vitro* cultured cells were harvested and the prerinced cell suspension prepared.

Centrifuging was then performed to obtain a cell pellet, and the supernatant was discarded. The cells were gently resuspended in the prewarmed (37°C) PBS containing the chemical dye. The mixture then passively diffused into the cultured cells, and an intracellular chemical reaction occurred, causing the colorless and nonfluorescent dye components to form fluorescent dye-protein conjugates. After a 15-minute incubation period at 37°C , the cells were pelleted by centrifugation and resuspended in HBSS. The dye-labeled cells could then be observed by fluorescence microscopy, and this allowed for *in vivo* tracing.

Semiquantitative Histological Scoring

The histological scoring system used was that of the Wakitani score [14]. This examined five categories including cell morphology, matrix-staining, surface regularity, thickness of cartilage, and integration with adjacent host cartilage with a maximum score of 14 (poorest result). The cell morphology was graded from 0 (for tissue that was normal when compared with the adjacent, uninjured cartilage) to 4 points (when cartilage tissue was absent). Matrix staining, or the degree of metachromasia, was graded from 0 (for tissue that was normal when compared with the adjacent, uninjured cartilage) to 3 points (no metachromatic staining).

Surface regularity, or the proportion of the surface of the defect that appears smooth when compared with the entire surface, was graded from 0 (when more than three quarters of the surface

was smooth) to 3 points (when less than one quarter of the surface was smooth). The thickness of cartilage, or the average thickness of cartilage in the defect when compared with the surrounding cartilage, was graded from 0 (when the average thickness of the cartilage in the defect was more than two-thirds that of the surrounding cartilage) to 2 points (when the average thickness was less than one-third that of the surrounding cartilage). Integration of the neocartilage with the host cartilage was graded from 0 (no gap between the neocartilage and host cartilage) to 2 points (a complete lack of integration). Three researchers familiar with cartilage work and not involved in this project assessed the slides independently. They were all blinded to reduce observational bias.

Statistics

Statistical analysis was provided by our biostatistician. The Kruskal-Wallis test was used to test for significant differences among the three groups, and pairwise comparison was performed using the Mann-Whitney test.

RESULTS

Macroscopic Observations

No signs of osteoarthritis such as osteophytes, cyst formation, cartilage erosion, or synovial proliferation were observed in any of the knees at any sampling interval despite the fact that a large proportion of the weight-bearing surface was occupied by the defect. At 6 weeks, partial filling of the defects was seen in typical MSC-treated and HA-treated specimens, and there was

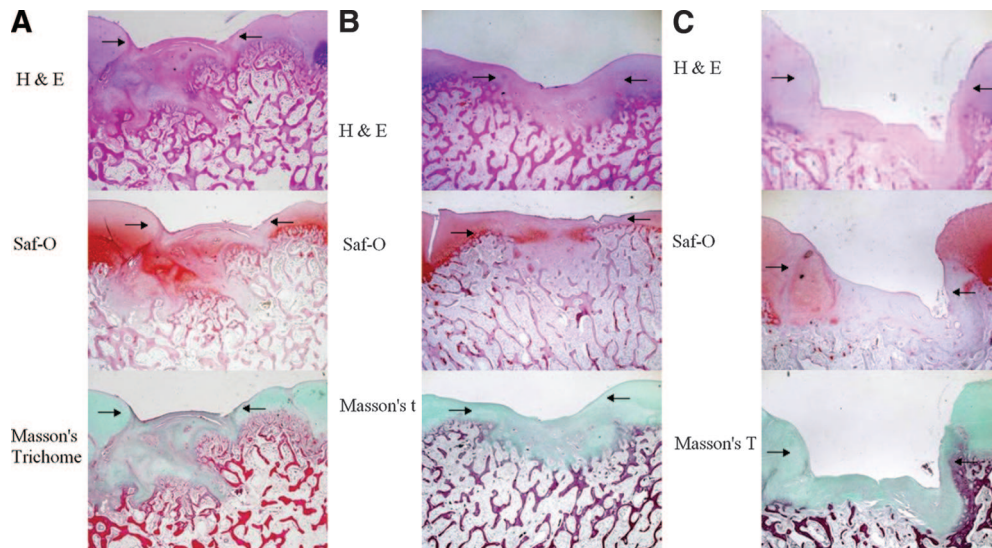


Figure 3. Microimages of the repaired chondral defects at 6th week. **(A):** Typical histological pictures of the defect with MSCs + hyaluronic acid (HA) at 6 weeks; $\times 12.5$ microscopy. Positions of defects created are indicated by arrows. **(B):** Typical histological pictures of the defect with HA at 6 weeks; $\times 12.5$ microscopy. Positions of defects created are indicated by arrows. **(C):** Typical histological pictures of the defect with saline at 6 weeks; $\times 12.5$ microscopy. Positions of defects created are indicated by arrows.

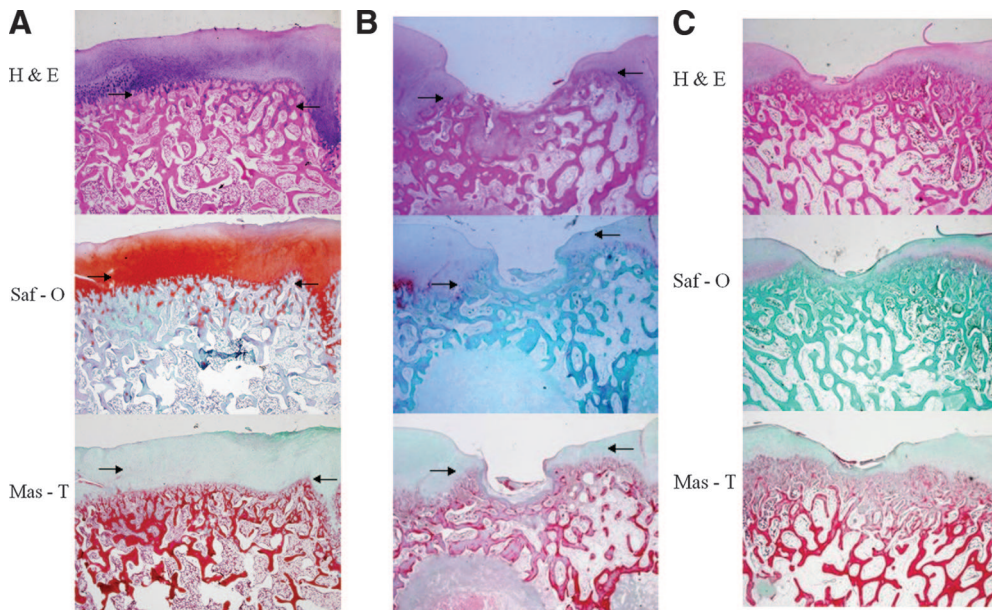


Figure 4. Microimages of repaired chondral defects at 12th week. **(A):** Typical histological pictures of the defect with MSCs + hyaluronic acid (HA) at 12 weeks; $\times 12.5$ microscopy. Positions of defects created are indicated by arrows. **(B):** Typical histological pictures of the defect with HA at 12 weeks; $\times 12.5$ microscopy. Positions of defects created are indicated by arrows. **(C):** Typical histological pictures of the defect with saline at 12 weeks; $\times 12.5$ microscopy. Positions of defects created are indicated by arrows.

not much difference in the appearance of specimens from both these groups (Fig. 2A, 2B). There was no healing seen in the other control group that was treated with saline and, at 6 weeks, the margins of the defects were clearly distinguishable, and there was minimal filling with reparative tissue (Fig. 2C).

At 12 weeks, the typical macroscopic appearance of the MSC-treated specimens indicated marked improvement of the filling of the defects compared with the two controls (Fig. 2D). Almost complete healing was seen in typical MSC-treated specimens, and the reparative tissue was similar to hyaline cartilage and, in most specimens, showed good integration of tissue at the margins with smooth surfaces and good thickness. Partial filling of the defect with nonhyaline repair tissue was seen in the HA-treated control group, which still demonstrated clearly discernible

edges and irregular surfaces (Fig. 2E). There was no healing seen in the other control group treated with saline (Fig. 2F).

Histological Observations

6 Weeks After the Operation. The appearance of the repair tissue in the MSC-treated group was comparable with hyaline cartilage but, in some areas, metachromatic staining was faint or absent (Fig. 3). This repair tissue was thin, and there was relatively poor integration with the normal cartilage. The defects in the HA-treated groups were partially filled with fibrocartilage with patchy areas of metachromatic staining. The negative control group treated with saline demonstrated poor healing and the reparative tissue, if any, was very thin with an irregular surface.

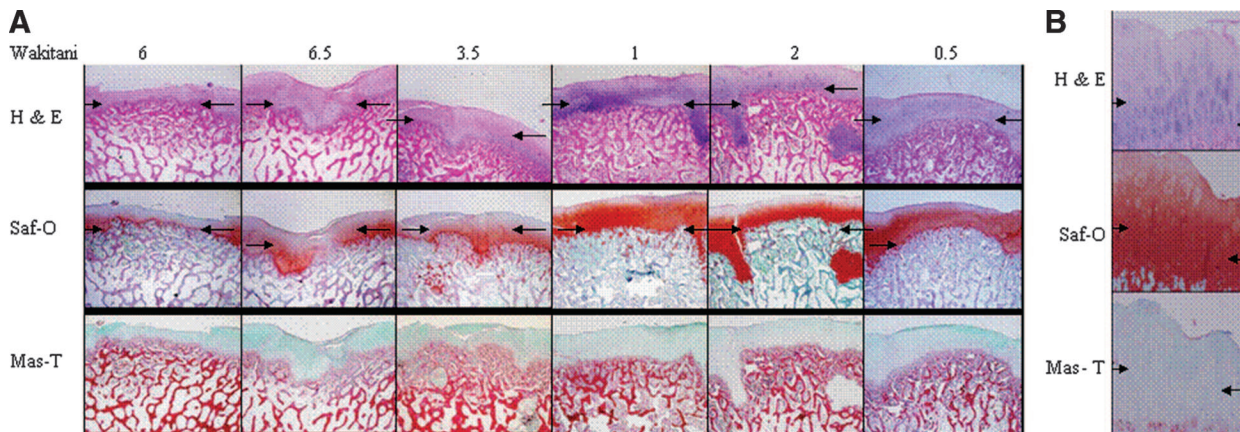


Figure 5. Microimages of the samples in experimental group. **(A):** Histological pictures ($\times 12.5$ microscopy) of all six MSC-treated specimens at 12 weeks. All six specimens show almost complete healing of the chondral defects with intense metachromasia. **(B):** Typical histological picture ($\times 40$ microscopy) of an MSC-treated specimen at 2 weeks. The tissue is hyaline-like with good integration, thickness, and surface regularity. Intense metachromasia is demonstrated. The cells resembled well-differentiated chondrocytes and were surrounded by metachromatic matrix. Abbreviations: Mas-T, Masson's trichome; Saf-O, Safranin O.

12 Weeks After the Operation. The differences among the three groups became clearer. There was marked improvement in the quality of the repair tissue seen in the MSC-treated group compared with the two controls.

The tissue was hyaline-like, with good integration, thickness, and surface regularity (Fig. 4A). Intense metachromasia was also demonstrated in most specimens (Fig. 5A), and most of the chondrocytes had an appearance comparable with that of hyaline cartilage. At higher magnification, the cells resembled well-differentiated chondrocytes and were surrounded by metachromatic matrix (Fig. 5B). The defects in both the controls were minimally filled with a thin, irregular fibrous tissue with minimal metachromatic staining (Fig. 4B, 4C).

Histological assessment of specimens treated with CFDA-SE-labeled MSCs under fluorescence microscopy confirmed that the injected cells were found in the neocartilage (Fig. 6). In our immunohistochemistry stainings (Fig. 7), type I collagen was distributed only at the surface of the regenerated cartilage-like tissue, and type II collagen was distributed throughout the whole neocartilage. This distribution pattern is similar to that of the normal cartilage.

Histological Grading

At 6 weeks, the semiquantitative Wakitani histological scores were 7, 7, and 4 for the MSC-treated, 7, 8, and 8.5 for the HA-treated, and 14, 13, and 10 for the saline-treated groups, respectively (Table 1). The mean Wakitani scores for the three groups at 6 weeks were 6 (MSC-treated), 7.8 (HA-treated), and 12.3 (saline-treated), respectively. Statistical analysis using the Kruskal-Wallis test showed that, overall, there was a significant difference among the three groups ($p < .05$). Pairwise comparison using the Mann-Whitney test showed no significant difference between MSCs versus HA, MSCs versus saline, and HA versus saline.

At 12 weeks, the Wakitani scores were 6, 0.5, 6.5, 3.5, 1, and 2 for the MSC-treated, 11, 11, 8, 7.5, 10, and 9.5 for the HA-treated, and 10, 12, 12, 12, 14, and 12 for the saline-treated groups, respectively. The mean Wakitani scores for the three groups at 12 weeks were 3.3 (MSC-treated), 9.5 (HA-treated), and 12.0 (saline-treated), respectively. There was marked improvement in the quality of the repair tissue seen in the MSC-treated group compared with the two controls, and this correlated well to both the macroscopic and histological observations.

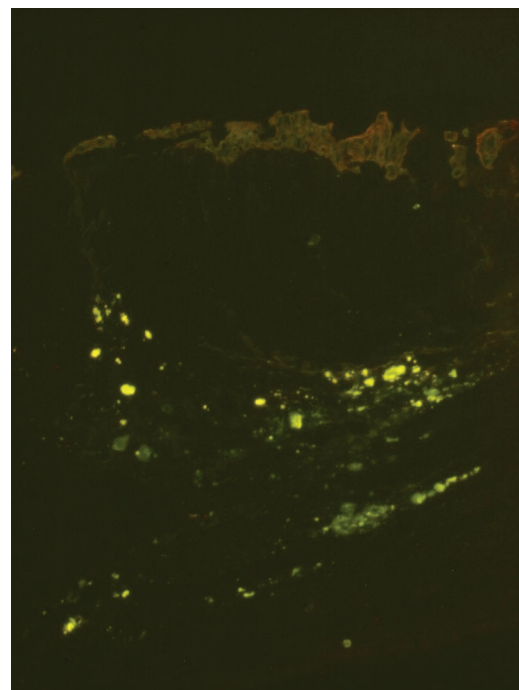


Figure 6. MSCs labeled with carboxyfluorescein diacetate succinimidyl ester in vitro allowed in vivo tracing, and the injected MSCs were confirmed to be found in the neocartilage.

Statistical testing using the Kruskal-Wallis test showed an overall significant difference among the three groups ($p < .001$). Pairwise comparison using the Mann-Whitney test showed that there was a significant difference between MSCs versus HA ($p < .006$) and between MSCs versus saline ($p < .006$).

Complications

Two of the MSC-treated and two of the HA-treated knees had large effusions following the injections. These were aspirated before the subsequent injections were given. The effusions subsequently resolved without any evidence of infection, and there was no interference with the pigs' movements or feeding. The likely reason for the reaction has been investigated by

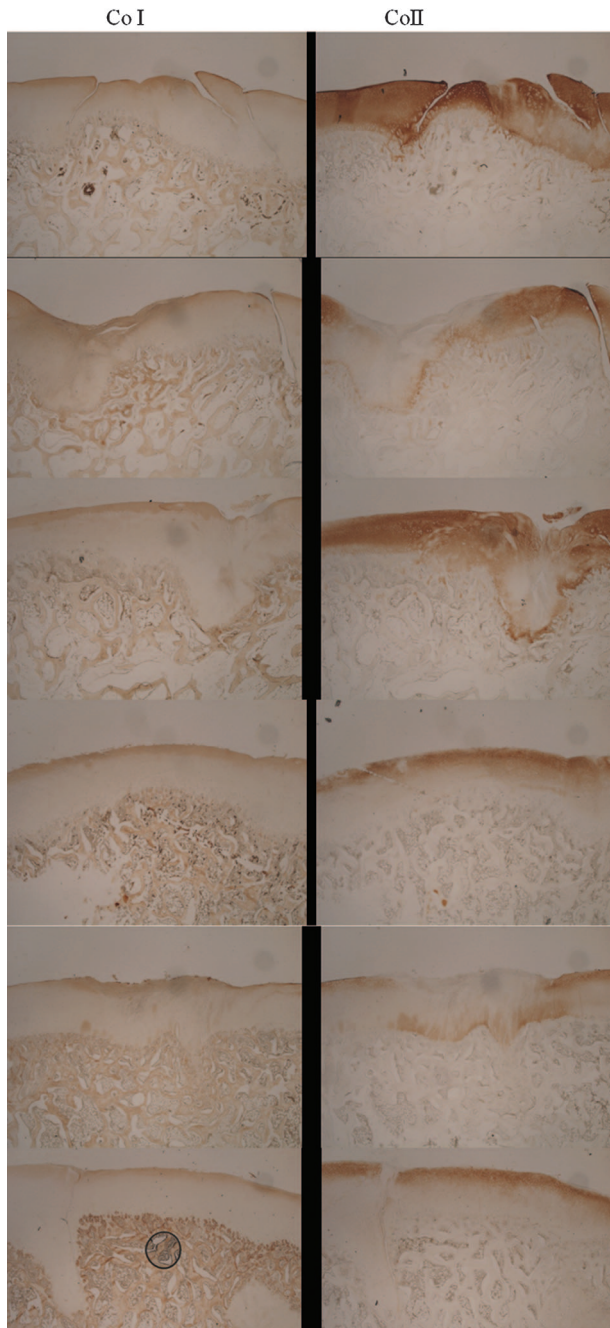


Figure 7. Immunohistochemistry staining using monoclonal antibodies against collagen types I and II (all six MSC-treated specimens at 12 weeks). Abbreviations: CoI, collagen type I; CoII, collagen type II.

several authors [15, 16] and can be attributed to a specific immunogenic protein species in the HA used (hylan G-F 20).

DISCUSSION

We wanted to test our hypothesis that intra-articularly injected MSCs that were suspended in HA could “hone” in to the site of injury and adhere, proliferate, and regenerate cartilage. To the best of our knowledge, this is a first in the literature that the direct regeneration of cartilage in a large chondral defect has been demonstrated by this injected technique. Our results at 6

Table 1. Summary of Wakitani scores at 6 and 12 weeks

Group	Number of specimens	Wakitani scores
6 Weeks		
MSC-treated	3	7
		7
		4
HA-treated	3	7
		8
		8.5
Saline-treated	3	14
		13
		10
		10
12 Weeks		
MSC-treated	6	6
		0.5
		6.5
		3.5
		1
HA-treated	6	2
		11
		11
		8
		7.5
		10
Saline-treated	6	9.5
		10
		12
		12
		12
		14
		12

Abbreviation: HA, hyaluronic acid.

weeks in the MSC-treated group showed partial healing of cartilage histologically and morphologically, whereas the results at 12 weeks in the MSC-treated group showed definite evidence of improved healing as compared with the two control groups (statistically significant with $p < .006$). In vivo tracing techniques using CFDA-SE labeled cells and fluorescence microscopy demonstrated that the injected MSCs were present in the neocartilage.

Mesenchymal stem cell-based therapies for the regeneration of cartilage have gained popularity over the last few years. In principle, the ultimate goal is to induce and expand multipotent MSCs at the site of interest down a signaled pathway into an end-stage phenotype. There are two different approaches to this. One is to implant cells directly or use a suitable matrix or scaffold seeded with chondrogenitor cells and signaling substances [17].

The alternative is to differentiate stem cells in vitro and implant a mature construct. The ability of stem cells to differentiate and adhere to scaffolds such as matrices of hyaluronan derivatives [18] and gelatin-based resorbable sponge matrices [19] has been investigated and proven.

Most studies presume that scaffolds are required for the regeneration of cartilage. It is ventured that loads and fluid movements would simply prevent cells from thriving where they are needed. However, studies have shown that MSCs can survive and thrive without a scaffold, and injected stem cells have been recovered in viable form in a goat knee with simulated arthritis [20]. This forms the basis of our experiment.

The ability of our marrow-derived mesenchymal stem cells to differentiate along both the osteo- and chondrolineages has been well established in our lab by von Kossa staining and collagen type II immunostaining, respectively. This has also been verified by many other authors [21, 22]. There are several

distinctive advantages of using MSCs over chondrocytes. First, it has been shown in some studies that immature constructs using MSCs integrate better [23, 24]. Martin and Buckwalter [25] have shown that telomeres shorten with age in chondrocytes as they do in other cells. This would mean that, in an older patient, the autologous chondrocytes that are reimplanted could suffer the fate of earlier degeneration. Animal experiments performed by one of our authors [26] comparing chondrocytes to MSC transfer for repair of chondral defects have clearly demonstrated that the joints repaired with chondrocytes showed degenerative changes in the repaired cartilage within 36 weeks, whereas the joints repaired by MSCs were still intact at that time. Finally, MSCs can regenerate not only cartilage but also the underlying subchondral bone [27] and would thus be able to resurface osteochondral defects as well.

The response associated with normal wound healing is not seen in partial-thickness cartilage defects, and this has been clearly demonstrated in our saline-treated negative control groups at both 6 and 12 weeks. In addition to its avascularity, there are many other possible reasons for this phenomenon. The presence of an inhibitor of wound healing [28, 29] in the extracellular matrix that impairs cell migration or adherence to the damage surface has been found. A study by Maniwa [30] proved that HA coats the surface of the articular cartilage and shares space in the cartilage among collagen fibrils and sulfated proteoglycans. An *in vitro* rabbit study [31] also illustrated that the rate of synovial cell migration was enhanced with HA alone, and HA increased chondrocyte migration in the presence of basic fibroblast growth factor. Hyaluronan-based polymers have been shown to enhance the natural healing process of osteochondral defects in animals [32]. These hyaluronan-based materials possess a unique biochemical composition that recreates an embryonic-like environment, which, as hypothesized, may be favorable for the regenerative process [33, 34]. Thus, we postulate that HA might facilitate the migration and adherence of MSCs or MSC-like cells (probably from synovium) to the defect. This may possibly explain the fact that the HA-treated groups demonstrated some form of partial healing at 6 weeks. However, this repair tissue was of inferior quality (possibly due to insufficient MSCs localized to the site of injury) and was shown to further deteriorate by 12 weeks.

The chondroprotective properties of HA have been demonstrated in several animal studies [35, 36]. In the osteoarthritis models of these studies, cartilage degradation was less in the HA-treated joints. HA also has significant effects on inflammatory mediators, which have deleterious results on MSCs. A canine study by Comer et al. [37] showed that, although tumor necrosis factor- α and its receptor were not evident in canine cartilage treated with HA, they were observed in untreated cartilage. In rabbit synovium, HA also reduced the expression of

two key mediators in cartilage degradation—interleukin-1- β and stromelysin [38]. Similar studies [39, 40] demonstrating the cartilage protective effects of HA strengthen our other postulation that its anti-inflammatory properties provide a conducive environment for the injected MSCs to migrate, proliferate, and differentiate at the site of injury. LaBarge's paper [41] suggests that there are two temporarily distinct injury-related signals, one that first induce MSCs to hone in to the site of injury and a second local signal that induces differentiation of MSCs into the relevant cell type to facilitate repair of the injured tissue. Our results suggest that MSCs require time to differentiate and proliferate, as evidenced by the progressively better results achieved as we went from 6 to 12 weeks. HA probably played an important secondary role in this process of cartilage regeneration but, on its own, it cannot produce sufficient biomechanically robust tissue that can withstand loads. We acknowledge several weaknesses in our study. In two out of the six MSC-treated specimens at 12 weeks, large fissures were seen on one side of the defect. This may indicate a problem with the integration of the neocartilage.

We understand that a potential deterioration of this neocartilage could be observed if we had a longer period of follow-up. We also noted anecdotally that there could be a dose-dependent response to the number of MSCs injected. However, as our number of animals was small, no comment pertaining to this was made in the Results. These questions will be answered in our new study following this pilot project. Lastly, we acknowledge the fact that the effect seen in this animal study could be different in human subjects.

ACKNOWLEDGMENTS

We acknowledge the invaluable contributions of the following people: Associate Professor Pierce Chow, Director, Department of Experimental Surgery, Singapore General Hospital; Robert Ng, Senior Manager, Department of Experimental Surgery, Singapore General Hospital; Dr. Lai Siang Hui, Department of Pathology, Singapore General Hospital; Chong Sue Wee, National University of Singapore; Dr. Yan Xiuyuan, Biostatistician, Clinical Trials and Epidemiology Research Unit, Singapore; Trier Lau, Raffles Junior College; Wang Ziting, Raffles Junior College. This work was funded by a grant from the National Medical Research Council.

DISCLOSURE OF POTENTIAL CONFLICTS OF INTEREST

The authors indicate no potential conflicts of interest.

REFERENCES

- Fuller JA, Ghadially FN. Ultrastructural observations on surgically produced partial-thickness defects in articular cartilage. *Clin Orthop* 1972; 86:193–205.
- Ghadially FN, Thomas I, Oryschak AF et al. Long-term results of superficial defects in articular cartilage: A scanning electron-microscope study. *J Pathol* 1977;121:213–217.
- Mankin HJ. Current Concepts Review. The response of articular cartilage to mechanical injury. *J Bone Joint Surg* 1982;64:460–466.
- Meachim G. The effect of scarification on articular cartilage in the rabbit. *J Bone Joint Surg* 1963;45B:150–161.
- Convery FR, Akeson WH, Keown GH. The repair of large osteochondral defects. An experimental study in horses. *Clin Orthop* 1972;82: 253–262.
- DePalma AF, McKeever CD, Subin DK. Process of repair of articular cartilage demonstrated by histology and autoradiography with titrated thymidine. *Clin Orthop Relat Res* 1966;48:229–242.
- Mitchell N, Shepard N. The resurfacing of adult rabbit articular cartilage by multiple perforations through the subchondral bone. *J Bone Joint Surg* 1976;58:230–233.
- Salter RB, Simmonds DF, Malcolm BW et al. The biological effect of continuous passive motion on the healing of full-thickness defects in articular cartilage. An experimental investigation in the rabbit. *J Bone Joint Surg* 1980;62:1232–1251.
- Coletti MJ, Akeson WH, Woo SL. A comparison of the physical behaviour of normal articular cartilage and the arthroplasty surface. *J Bone Joint Surg* 1972;54:147–160.
- Furukawa T, Eyre DR, Koide S et al. Biochemical studies on repair cartilage resurfacing experimental defects in the rabbit knee. *J Bone Joint Surg* 1980;62:79–89.
- O'Driscoll SW. Current Concepts Review—The healing and regeneration of articular cartilage. *J Bone Joint Surg Am* 1998;80:1795–1812.

- 12 Murphy JM, Fink DJ, Hunziker EB et al. Stem cell therapy in a caprine model of osteoarthritis. *Arthritis Rheum* 2003;48:3464–3474.
- 13 Ouyang HW, Goh JC, Lee EH. Use of bone marrow stromal cells for tendon graft-to-bone healing: Histological and immunohistochemical studies in a rabbit model. *Am J Sports Med* 2004;32:321–327.
- 14 Wakitani S, Goto T, Pineda SJ et al. Mesenchymal cell-based repair of large, full-thickness defects of articular cartilage. *J Bone Joint Surg* 1994;76:579–592.
- 15 Sasaki M, Miyazaki T, Nakamura T et al. Immunogenicity of hylan G-F 20 in guinea pigs and mice. *J Rheumatol* 2004;31:943–950.
- 16 Hamburger M, Settles M, Teutsch J. Identification of an immunogenic candidate for the elicitation of severe acute inflammatory reactions (SAIRs) to hylan G-F 20. *Osteoarthritis Cartilage* 2005;13:266–268.
- 17 Jackson DW, Simon TM. Tissue engineering principles in orthopaedic surgery. *Clin Orthop Relat Res* 1999;(suppl 367):S31–S45.
- 18 Solchaga LA, Yoo JU, Lundberg M et al. Hyaluronan-based polymers in the treatment of osteochondral defects. *J Orthop Res* 2000;18:773.
- 19 Ponticello MS, Schinagl RM, Kadiyala S et al. Gelatin-based resorbable sponge as a carrier matrix for human mesenchymal stem cells in cartilage regeneration therapy. *J Biomed Mater Res* 2000;52:246.
- 20 Barry FP. Mesenchymal stem cell therapy in joint disease. In: Bock G, Goode J, eds. *Tissue Engineering of Cartilage and Bone*. No. 249 (Novartis Foundation Symposia). Chichester, West Sussex: John Wiley & Sons Publication, 2002:86–966.
- 21 Martin GR, Evans MJ. Differentiation of clonal lines of teratocarcinoma cells: Formation of embryoid bodies in vitro. *Proc Natl Acad Sci U S A* 1975;72:1441–1445.
- 22 Caplan AI. Mesenchymal stem cells. *J Orthop Res* 1991;9:641.
- 23 Obradovic B, Martin I, Padera RF et al. Integration of engineered cartilage. *J Orthop Res* 2001;19:1089–1097.
- 24 Vunjak-Novakovic G. The fundamentals of tissue engineering: Scaffold and bioreactors. In: Bock G, Goode J, eds. *Tissue Engineering of Cartilage and Bone*. No. 249 (Novartis Foundation Symposia). Chichester, West Sussex: John Wiley & Sons Publication, 2002:34–46.
- 25 Martin JA, Buckwalter JA. Aging, articular cartilage chondrocyte senescence and osteoarthritis. *Biogerontology* 2002;3:257.
- 26 Hui JH, Chen F, Thambyah A et al. Treatment of chondral lesions in advanced osteochondritis dissecans: A comparative study of the efficacy of chondrocyte mesenchymal stem cells, periosteal graft, and mosaicplasty in animal models. *J Pediatr Orthop* 2004;24:427.
- 27 Hunziker EB, Rosenberg LC. Repair of partial-thickness defects in articular cartilage: Cell recruitment from the synovial membrane. *J Bone Joint Surg* 1996;78:721–733.
- 28 Hunziker EB, Kapfinger E. Removal of proteoglycans from the surface of defects in articular cartilage transiently enhances coverage by repair cells. *J Bone Joint Surg Br* 1998;80:144–150.
- 29 Balazs E. The physical properties of synovial fluid and the specific role of hyaluronic acid. In: Helfet AJ, ed. *Disorders of the Knee*. Philadelphia: J. B. Lippincott, 1982:61–74.
- 30 Maniwa S, Ochi M, Motomura T et al. Effects of hyaluronic acid and basic fibroblast growth factor on motility of chondrocytes and synovial cells in culture. *Acta Orthop Scand* 2001;72:299–303.
- 31 Yoshioka M, Shimizu C, Harwood FL et al. The effects of hyaluronan during the development of osteoarthritis. *Osteoarthritis Cartilage* 1997; 5:251–260.
- 32 Solchaga LA, Yoo JU, Lundberg M et al. Hyaluronan-based polymers in the treatment of osteochondral defects. *J Orthop Res* 2000;18:773–780.
- 33 Toole BP, Banerjee S, Turner R et al. Hyaluronan-cell interactions in limb development. In: Hinchliffe JR, Hurle JM, Summerbell D, eds. *Developmental Patterning of the Vertebrate Limb*. New York: Plenum, 1991:215–223.
- 34 Toole BP. Hyaluronan in morphogenesis. *J Intern Med* 1997;242:35–40.
- 35 Shimizu C, Yoshioka M, Coutts RD et al. Long-term effects of hyaluronan on experimental osteoarthritis in the rabbit knee. *Osteoarthritis Cartilage* 1998;6:1–9.
- 36 Kobayashi K, Amiel M, Harwood FL et al. The long-term effects of hyaluronan during the development of osteoarthritis following partial meniscectomy in a rabbit model. *Osteoarthritis Cartilage* 2000;8: 359–365.
- 37 Comer JS, Kincaid SA, Baird AN et al. Immunolocalization of stromelysin, tumour necrosis factor (TNF) alpha, and TNF receptors in atrophied canine articular cartilage treated with hyaluronic acid and transforming growth factor beta. *Am J Vet Res* 1996;57:1488–1496.
- 38 Takahashi K, Goomer RS, Harwood F et al. The effects of hyaluronan on matrix metalloproteinase-3 (MMP-3), interleukin-1 beta (IL-1 beta), and tissue inhibitor of metalloproteinase-1 (TIMP-1) gene expression during the development of osteoarthritis. *Osteoarthritis Cartilage* 1999;7:182–190.
- 39 Yasui T, Akatsuka M, Tobetto K et al. Effects of hyaluronan on the production of stromelysin and tissue inhibitor of metalloproteinase-1 (TIMP-1) in bovine articular chondrocytes. *Biomed Res* 1992;13: 343–348.
- 40 Nonaka T, Kikuchi H, Ikeda T et al. Hyaluronic acid inhibits the expression of u-PA, PAI-1, and u-PAR in human synovial fibroblasts of osteoarthritis and rheumatoid arthritis. *J Rheumatol* 2000;27: 997–1004.
- 41 LaBarge MA, Blau HM. Biological progression from adult bone marrow to mononucleate muscle stem cell to multinucleate muscle fiber in response to injury. *Cell* 2002;111:589–601.

Injectable Mesenchymal Stem Cell Therapy for Large Cartilage Defects A Porcine Model

Kevin B.L. Lee, James H.P. Hui, Im Chim Song, Lenny Ardany and Eng Hin Lee
Stem Cells 2007;25;2964-2971; originally published online Jul 26, 2007;
DOI: 10.1634/stemcells.2006-0311

This information is current as of December 3, 2007

**Updated Information
& Services**

including high-resolution figures, can be found at:
<http://www.StemCells.com/cgi/content/full/25/11/2964>