

Histological Evaluation of Bone Marrow Derived Stem Cell Therapy on Experimentally Induced Osteoarthritis in Albino Rats' Knee Joint

Samir Mahmoud Nada, Nagla Mohamed Salama, Mary Atia Morcos and Amal Elham Fares

Histology Department, Faculty of Medicine, Cairo University, Cairo, Egypt
amalfares@gmail.com

Abstract: Aim of work: This work aims to evaluate the efficacy of intra-articular injection of bone marrow derived-mesenchymal stem cells (MSCs) in treatment of mono-iodoacetate (MIA) induced osteoarthritis in rat knee joint monitored by histological and immunohistochemical methods. **Material and methods:** this study was carried out on 45 adult male albino rats. They were classified into 4 groups: group I (control group), group II (osteoarthritic group) in which rats received 1 mg of MIA and sacrificed after 2 weeks and after 4 weeks, group III (stem cell treated group) in which rats received MSCs 2 weeks after MIA injection or 4 weeks after MIA and sacrificed 2 weeks later and group IV (untreated group) in which rats received PBS 2 weeks after MIA injection or 4 weeks after MIA and sacrificed 2 weeks later. Sections were taken from rats' knee joints and stained with Hematoxylin and Eosin, toluidine blue, immunohistochemical stains for collagen type II. Sections were examined by light microscopy. The mean articular cartilage (AC) thickness, optical density of cartilage matrix proteoglycan and area percent of collagen type II immunoreactivity were measured using image analyzer and statistically analyzed. **Results:** Sections of group II showed features of osteoarthritis in the form of disorientation & degeneration of chondrocytes, Exfoliation of the superficial part of AC with many osteoblasts and osteoclasts were noticed with significant reduction in cartilage thickness, optical density of AC matrix and area % of collagen type II immunostaining compared to control. Sections of AC in the MSCs treated group showed apparent improvement of the osteoarthritic features in the form of increase in the AC thickness with normal zonation and proliferation of chondrocyte with significant increase in optical density of AC matrix and collagen type II immunoreactivity. Sections of the AC in group IV (untreated group) showed deterioration of the OA features with complete loss of zonation and many degenerated chondrocytes. **Conclusion:** Treatment with bone marrow derived mesenchymal stem cells (MSCs) could significantly treat the osteoarthritic changes induced by MIA in rat knee joint. [Samir Mahmoud Nada, Nagla Mohamed Salama, Mary Atia Morcos and Amal Elham Fares. **Histological Evaluation of Bone Marrow Derived Stem Cell Therapy on Experimentally Induced Osteoarthritis in Albino Rats' Knee Joint.** *J Am Sci* 2015;11(6):226-236]. (ISSN: 1545-1003). <http://www.jofamericanscience.org>. 26

Key words: Knee joint- AC- osteoarthritis- MIA- MSCs.

1. Introduction:

Osteoarthritis is characterized by joint pain and dysfunction and, in advanced stages, joint contractures, muscle atrophy and limb deformity (Andras *et al.*, 2012). The pathogenesis of OA involves interactions of joint tissues, joint biomechanics, and biochemical pathways. Many characteristics, such as age, genetic background and obesity predispose an individual to the development of OA. In conjunction with aberrant joint biomechanics in the form of injury, overload, or joint instability, this predisposition may lead to altered biochemical pathways including those involved in cytokine and growth factor signaling, or matrix biosynthesis and turnover. These altered pathways lead to the development and progression of tissue damage in OA which present clinically as radiographic changes in bone and cartilage and joint pain. The presentation of pain is also affected by psychosocial and socioeconomic factors as well as the presence of comorbidities (Thumboo *et al.*, 2002). The presence of pain may act to alter biochemical pathways leading to

further development and progression of OA. In addition, pain leads to disability and distress which lead to increased pain perception (Tuominen *et al.*, 2007). The disruption of homeostasis results in increased water content and decreased proteoglycan content of the extracellular matrix and weakening of the collagen network due to decreased synthesis of type II collagen and increased breakdown of pre-existing collagen. Furthermore, there is increased apoptosis of chondrocytes. At first, compensatory mechanisms, such as increased synthesis of matrix molecules and proliferation of chondrocytes in the deeper layers of the cartilage, are able to maintain the integrity of the articular cartilage, but eventually loss of chondrocytes and changes in extracellular matrix predominate and osteoarthritic changes develop (Loeser, 2010).

Therapeutic approaches range from psychosocial, pharmacological, and physical therapy interventions to surgical replacement of degenerated joints. Effective long-term management of the disease proposes involvement of a sequential approach, the

details of which are based on disease severity at the time of diagnosis. Such treatment strategies ideally begin with information and education at the earliest stages of disease diagnosis. This is followed by self help interventions (including analgesics) then progresses to simple non-steroidal anti-inflammatory (NSAID) medications, corticosteroids, physical and occupational therapy and advanced (injections) non-surgical interventions. Finally, application of surgical procedures may be necessary (*Dieppe and Lohmander, 2005*).

Recently, *Matsumoto et al. (2009)* concluded that in OA, more generalized cartilage lesions and joint inflammation are present, thereby limiting the usefulness of focal treatments. In order to treat the joint as a whole, MSCs have been injected intra-articularly in pre-clinical and some initial clinical studies as a treatment for OA. The use of MSCs as a treatment option in cartilage regeneration is under extensive investigation (*Coleman et al., 2010*). In the study done by *Singh et al. (2014)* using stem cells as a treatment option for OA has shown significant improvements histopathologically and radiologically compared with untreated specimens. They can conclude from their study that stem cells are a promising source for treatment of OA even without the use of stem cell culture. However, studies with larger groups and longer follow-up are required to determine the use of stem cells as a therapeutic option.

2. Material and Methods:

a) Subjects:

This study was carried out on 45 adult male rats. The rats were randomly divided into 4 groups:

Group I (control group): Included 15 rats. Rats were injected in the right knee joint with a single dose of 0.5 ml of balanced saline solution (BSS). They were then subdivided into 3 subgroups:

Subgroup Ia: 5 rats were sacrificed after 2 weeks.

Subgroup Ib: 5 rats were sacrificed after 4 weeks.

Subgroup Ic: 5 rats were sacrificed after 6 weeks.

Group II (osteoarthritic group): Included 10 rats. Rats were injected in the right knee joint with a single dose of 1mg of MIA dissolved in 0.5 ml of balanced saline solution (BSS).

They were subdivided into 2 subgroups:

Subgroup IIa: 5 rats were sacrificed after 2 weeks.

Subgroup IIb: 5 rats were sacrificed after 4 weeks.

Group III (MSCs treated group): Included 10 rats. Rats were injected with MIA as group II then they were subdivided into 2 subgroups:

Subgroup IIIa: 5 rats were injected in the right knee with MSCs (1×10^6 cells suspended in 150 μ l Dulbecco's Phosphate Buffered Saline) 2 weeks after MIA injections then they were sacrificed 2 weeks after MSCs injection.

Subgroup IIIb: 5 rats were injected in the right knee with MSCs (1×10^6 cells suspended in 150 μ l Dulbecco's Phosphate Buffered Saline) 4 weeks after MIA injection then they were sacrificed 2 weeks after MSCs injection.

Group IV (untreated group): Included 10 rats. Rats were injected with MIA as group II then they were subdivided into 2 subgroups:

Subgroup IVa: 5 rats were injected with 150 μ l Phosphate Buffered Saline (the vehicle of stem cells) 2 weeks after MIA injection then they were sacrificed 2 weeks later.

Subgroup IVb: 5 rats were injected by with 150 μ l Phosphate Buffered Saline 4 weeks after MIA injection then they were sacrificed 2 weeks later.

Bone-marrow derived Mesenchymal stem cells (MSCs):

MSCs were isolated from rat bone marrow, propagated in culture and labeled with PKH26 dye. 1 million cells suspended in 150 μ l Dulbecco's Phosphate Buffered Saline (DPBS, GIBCO, NY, USA) were injected intra-articularly in the right knee joints of rats (*Protol et al., 2011*). They were supplied from Biochemistry department, Faculty of medicine, Cairo University under complete sterile condition and used immediately after preparation.

Drug: Mono-Iodoacetate (MIA):

It was purchased from Sigma-Aldrich Chemie GmbH (Sigma, St. Louis, MO, USA; cat #I2512) in the form of powder. 30 mg of the MIA powder were dissolved in 15 ml of balanced saline solution (BSS) and injected in the right knee joint in a dose of 0.5ml of the solution containing 1mg of MIA to induce osteoarthritis (*Guzman et al., 2003*).

b) Methods:

Dissection & processing of the samples:

The animals of all groups were sacrificed under anesthesia by intra-peritoneal injection of phenobarbital sodium (40mg/kg). The right knee joint was dissected, fixed in 10% buffered formalin solution. The specimens were decalcified using the chelating agent EDTA for 4 weeks with daily change of solution until softening of specimens. Then they were processed to form paraffin blocks. Serial sections of 5-7 μ m thickness were cut. Sections for immunohistochemical study were mounted on charged slides to avoid falling down of tissue during immunostaining. Specimens were fixed in 10% buffered formol saline. The specimens were decalcified using the chelating agent EDTA for 4 weeks with daily change of solution until softening of specimens. Then they were processed to form paraffin blocks. Serial sections of 5-7 μ m thickness were cut. Sections were stained by H&E, toluidine blue and immunohistochemical staining for collagen type II.

Morphometric study and statistical analysis

Morphometric measurements of articular cartilage thickness in H&E stained section, optical density of cartilage matrix in toluidine blue stained sections and area % of collagen II fibers in immunostained section were done using the image analyzer. Data obtained were statistically analyzed.

Data were obtained using "Leica Qwin 500 C" image analyzer computer system Ltd. (Cambridge, England). The image analyzer consisted of a color video camera (*Olympus*), colored monitor, hard disc of IBM personal computer connected to the microscope, and controlled by "Leica Qwin 500 C" software.

The following parameters were measured:

Articular cartilage thickness, Optical density of cartilage matrix and Area percent of collagen-II immunopositive matrix.

3. Results:

H&E stained sections from all control subgroups (Ia, Ib & Ic) revealed the same histological findings. They showed normal structure of the articular cartilage with its normal histological zones. The subchondral bone showed normal bone trabeculae and normal bone marrow cavities (*fig. 1*).

H&E stained sections of group II (osteoarthritic group) showed in subgroup IIa (2 weeks after MIA) apparent reduced cartilage thickness compared to control, disorientation of chondrocytes. Many chondrocytes showed small dark nuclei. Some chondrocytes appeared shrunken with hypereosinophilic cytoplasm (*fig. 2*). While in subgroup IIb (4 weeks after MIA), they revealed disorientation and clustering of chondrocytes, Subchondral bone shows many cracks exfoliation (*fig. 3*). Many osteoblasts and osteoclasts were noticed and in some sections, bone marrow showed decreased cellularity with few spindle shaped cells.

H&E stained sections of AC in the MSCs treated (subgroups IIIa & IIIb) showed apparent improvement of the osteoarthritic features in the form of increase in the AC thickness as compared to osteoarthritic group with normal zonation (*fig. 4*). However, proliferating chondrocytes were observed. Many chondrocytes appeared shrunken with dark nuclei and eosinophilic cytoplasm in subgroup IIIb.

Sections of the AC in the subgroup IVa (untreated group 4 weeks after MIA) showed deterioration of the OA features with apparent reduction in the articular cartilage thickness compared to control which was more obvious in subgroup IVb (untreated group 6 weeks after MIA). The AC of subgroup IVa revealed loss of normal zonation. Many chondrocytes with condensed dark nuclei could be observed. While in subgroup IVb irregular eroded

surface of AC with complete loss of zonation and degenerated chondrocytes were seen (*fig. 5*).

Toluidine blue stained sections in control group revealed dense staining of the extracellular matrix especially in the transitional and deep zones (*fig. 6*). While sections in both osteoarthritic groups (subgroups IIa & IIb) revealed reduction in toluidine blue staining (*fig. 7*). Examinations of sections of the AC of subgroup IIIa (MSCs treated group 2 weeks after MIA) and in subgroup IIIb (treated group 4 weeks after MIA) (*fig. 8*) revealed increase in the staining intensity of the extracellular matrix especially in the transitional zone with longitudinally arranged immunostained bundles in the deep zone. Toluidine blue stained-sections of the AC of subgroup IVa (untreated group 4 weeks after MIA) showed mild staining of the extracellular matrix of AC. While sections of subgroup IVb (untreated group 6 weeks after MIA) showed faint staining of the extracellular matrix of AC.

Immunohistochemical results few collagen type II stained sections in the control group revealed strong extracellular immunoreactivity in the superficial zone and moderate immunoreactivity in the transitional zone (*fig. 9*).

Concerning osteoarthritic group (group II) there was apparent decrease in the extracellular immunoreactivity in the subgroup IIa (2 weeks after MIA) which become more obvious in the subgroup IIb (4 weeks after MIA) (*fig.10*). The positive immunoreactivity had a patchy interrupted appearance. Sections in subgroup IIIa (treated group 2 weeks after MIA) and in subgroup IIIb (treated group 4 weeks after MIA) showed increased extracellular immunoreactivity with strong immunostaining in the superficial zone and moderate staining in the transitional and deep zones. Sections from subgroup IVa (untreated group 4 weeks after MIA) and subgroup IVb (untreated group 6 weeks after MIA), sections showed patchy interrupted extracellular immunoreactivity.

Morphometric Results

There was a significant decrease in the mean articular cartilage thickness of the osteoarthritic group (subgroups IIa & IIb) and untreated group (subgroups IVa & IVb) compared to control group. There was, also, a significant decrease in osteoarthritic group (subgroups IIa & IIb) and untreated group (subgroups IVa & IVb) versus treated group III.

The Morphometric results of both mean optical density of the AC matrix in toluidine blue stained sections and mean area % of collagen II in immunohistochemical stained sections revealed a significant decrease in osteoarthritic group (subgroups IIa & IIb) and untreated group (subgroups IVa & IVb)

compared to control group while there was no significant difference between treated group (subgroups IIIa & IIIb) and control. There was a significant decrease in (subgroups IIb) and untreated group (subgroups IVa & IVb) compared to treated group (subgroups IIIa & IIIb).

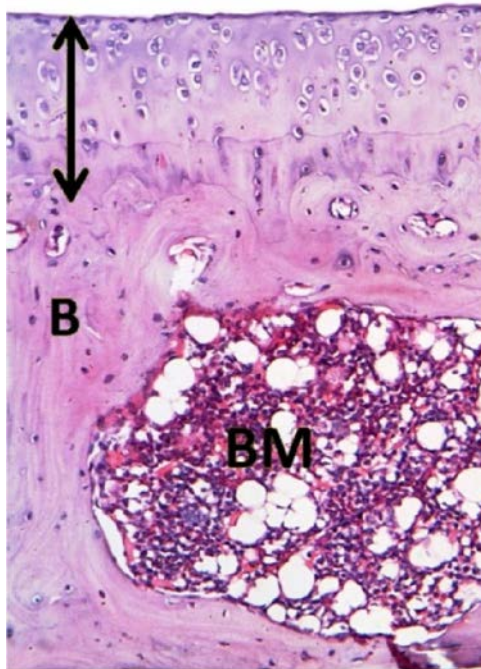


Fig. (1): A photomicrograph of a section from the control group showing the AC (line) and the subchondral bone (B) with normal bone trabeculae and normal bone marrow cavities (BM) (H&E x 200).

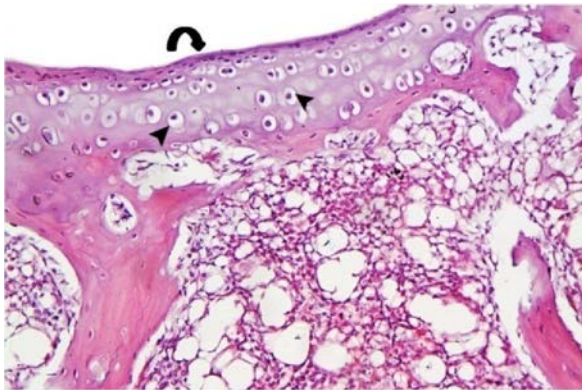


Fig. (2): A photomicrograph of a section of AC in subgroup IIa (osteoarthritic group 2 weeks after MIA) showing apparent reduced cartilage thickness. Disorientation of chondrocytes in the different zones and clusters of chondrocytes (curved arrow) in the superficial zones are observed. Many chondrocytes show condensed dark nuclei (arrowheads) (H&E x 200).

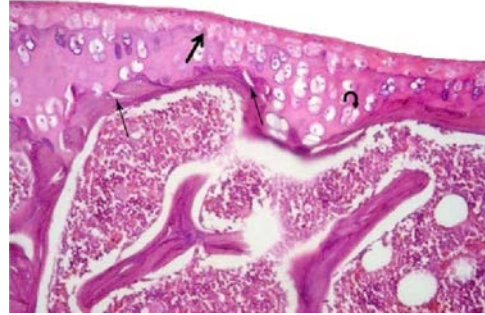


Fig. (3): A photomicrograph of section from subgroup IIb (osteoarthritic group 4 weeks after MIA) showing decrease in the AC thickness with loss of the superficial zone and part of transitional zone. Note shifting of the tide mark upwards (thick arrow). Disorientation of chondrocytes and many clusters of chondrocytes in the calcified zone can be seen (curved arrow). Subchondral bone shows many cracks (thin arrow) (H&E x 200).

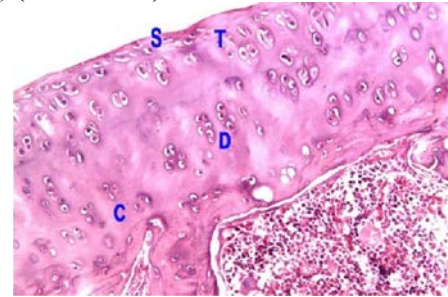


Fig. (4): A photomicrograph of AC section from subgroup IIIa (MSCs injected 2 weeks after MIA). There is apparent increase in the AC thickness with normal zonation: Superficial zone (S), transitional zone (T), deep zone (D) and calcified zone (C). The tide mark is not identified (H&E x 200).

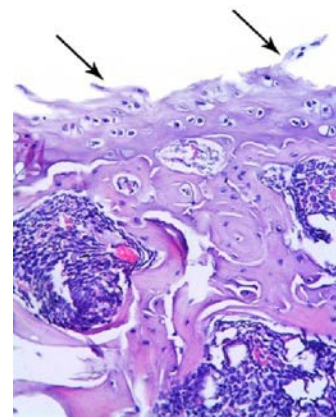


Fig. (5): A photomicrograph of subgroup IVb (untreated group 6 weeks after MIA) showing part of AC with marked decrease in thickness. Note loss and exfoliation of superficial and transitional zones of AC. Irregular surface (arrows) and complete loss of zonation can be seen (H&E x 200).

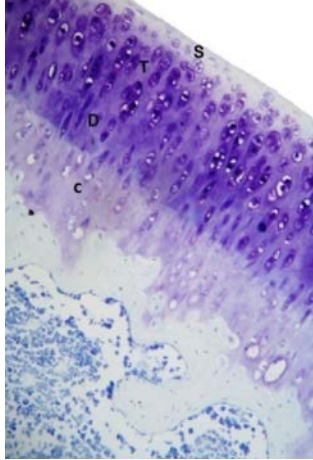


Fig. (6): A photomicrograph of the control group showing part of the AC stained with toluidine blue. The transitional zone (T) & deep zone (D) show dense staining of the extracellular matrix compared to superficial (S) & calcified (C) zones (Toluidine blue x 200).

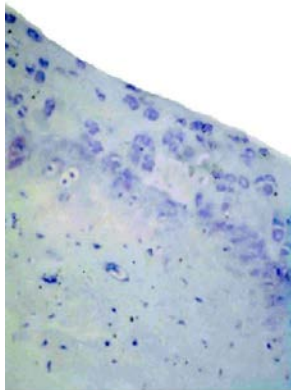


Fig. (7): A photomicrograph of a section of AC in subgroup IIb (osteoarthritic group 4 weeks after MIA) showing faint staining of the extracellular matrix of AC (Toluidine blue x 200).

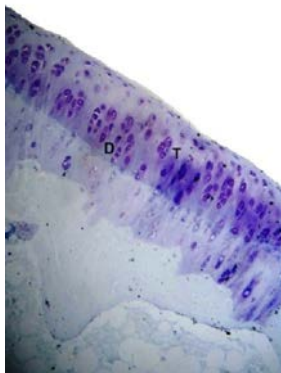


Fig. (8): A photomicrograph of a part of AC in subgroup IIIb (treated group) showing increase staining intensity of the transitional zone (T) and deep zone (D) (Toluidine blue x 200).

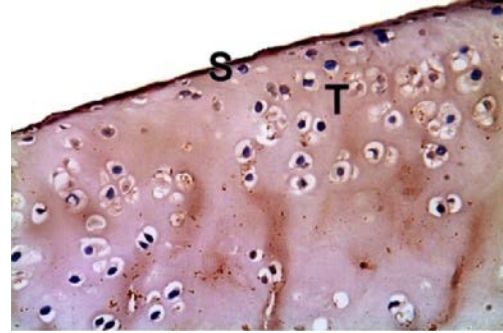


Fig. (9): A photomicrograph of a section in the AC from group I (control group) showing strong extracellular immunoreactivity in the superficial zone (S) and moderate immunoreactivity in the transitional zone (T) (Anti-Collagen-II immunostaining x400).

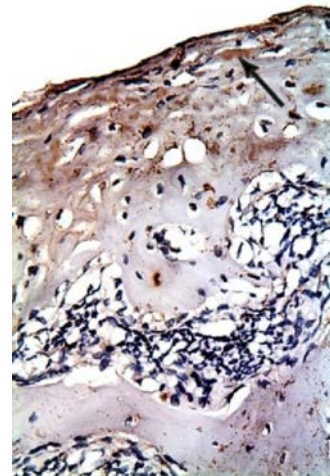


Fig. (10): A photomicrograph of a section in the AC from subgroup IIb (osteoarthritic group 4 weeks after MIA) showing patchy interrupted extracellular immunoreactivity (arrow) (Anti-Collagen-II immunostaining x400).

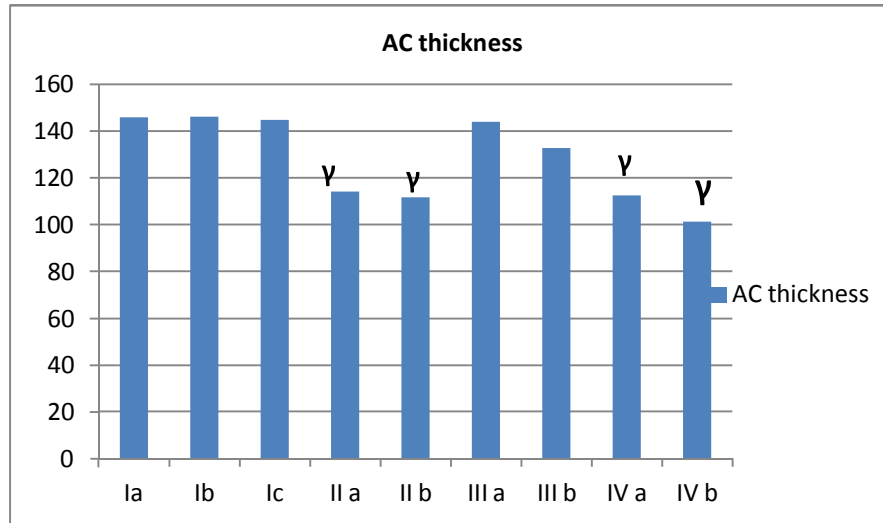
4. Discussion:

This work was performed to evaluate the efficacy of intra-articular injection of bone marrow derived-mesenchymal stem cells (MSCs) in treatment of Mono-iodoacetate (MIA) induced osteoarthritis in rat knee joint monitored by histological and immunohistochemical methods.

Light microscopic examination of H&E stained sections of the control group revealed the normal structure of the articular cartilage with its normal histological zones. The superficial zone of AC showed elongated chondrocytes while the transitional zone showed rounded chondrocytes present inside lacuna. The deep zone of the AC showed chondrocytes arranged in columns. The tide mark separated the deep zone from underlying calcified zone which contained small chondrocytes. It was shown by *Mason et al.*

(2001) that normal articular cartilage is composed of chondrocytes embedded within an extracellular matrix. It was stated by Lyons *et al.* (2006) that the boundary between calcified and non-calcified cartilage appears as a basophilic line in histological

sections, and is referred to as the tidemark. Its appearance is indicative of build-up of macromolecular debris, including DNA, which does not pass through the barrier between the non-calcified and calcified zones.

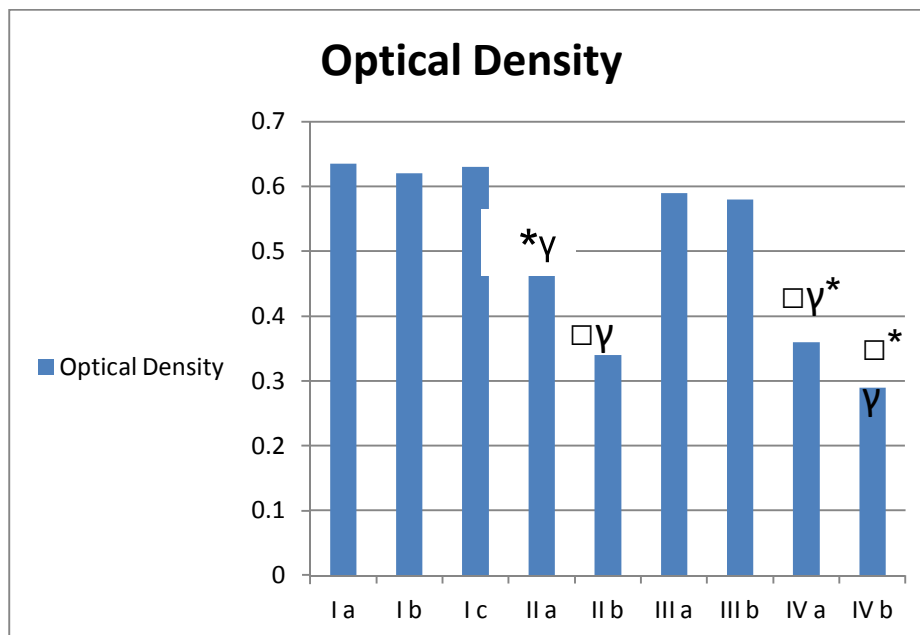


Histogram (1): comparing the mean articular cartilage thickness (in μm) in the studied groups.

* $P < 0.05$ compared to group I (subgroups Ia, Ib & Ic).

γ $P < 0.05$ compared to subgroup IIIa & IIIb.

Significant ($P < 0.05$).



Histogram (2): comparing the mean optical density of AC in the studied groups.

* $P < 0.05$ compared to group I (subgroups Ia, Ib & Ic).

\square $P < 0.05$ compared to subgroup IIIa.

γ $P < 0.05$ compared to subgroup IIIb.

Examination of sections of osteoarthritic group in **subgroup IIa** (2 weeks after MIA) showed apparent reduction in the mean articular cartilage thickness compared to the control group. This finding could be explained by the osteoarthritic changes caused by MIA injection that lead to decreased thickness of the AC. This finding coincides with the results reported by *Guzman et al. (2003)* who found that at day 14 after intra articular injection of MIA, some chondrocyte death and loss of matrix led to decreased thickness of the articular cartilage that was more evident at day 21 after MIA injection.

In the present study sections of **subgroup IIa** (2 weeks after MIA) showed disorientation of chondrocytes with clusters in the different zones. This finding could be attributed to the direct action of MIA on the cellular component of the articular cartilage. Similar results were found by *Al-Saffar et al. (2009)* who detected that MIA injection induces various histopathological changes like degeneration, cloning and disorganization of articular cartilage chondrocytes. Furthermore, *Loeser (2010) and Andras et al. (2012)* explained that there is increased apoptosis of chondrocytes. At first, compensatory mechanisms, such as increased synthesis of matrix molecules and proliferation of chondrocytes in the deeper layers of the cartilage, are able to maintain the integrity of the articular cartilage, but eventually loss of chondrocytes and changes in extracellular matrix predominate and osteoarthritic changes develop.

In **subgroup IIa**, many chondrocytes with small dark nuclei could be detected. Some chondrocytes appeared shrunken with hypereosinophilic cytoplasm. Some lacunae appeared empty. These findings could be attributed to apoptotic changes in the chondrocytes due to the destructive effect of MIA as explained by *Guzman et al. (2003)* who stated that MIA inhibits the activity of glyceraldehyde-3-phosphate dehydrogenase of the articular chondrocytes leading to disruption of the glycolytic energy metabolism and synthetic processes and eventually to cell death. Reports by *Musumeci et al. (2011)* suggested that cell death in OA occurs primarily via apoptosis or apoptosis like programmed cell death which is a distinct process compared to cellular necrosis.

The osteoarthritic changes were more obvious in **subgroup IIb** (4 weeks after MIA) exfoliation of the superficial zone and part of the transitional zone with shifting of the tide mark upwards could be seen. These results could be explained by the longer duration of the osteoarthritic disease with failure of the AC to repair. Similar results were found by *Kobayashi et al. (2003)* who reported that the changes of OA had been progressed from mild to moderate or severe with the more prolonged duration period of OA induction. In some sections of **subgroup IIb** the bone marrow

examination showed decreased cellularity with few spindle shaped cells. This finding may be explained by progression of osteoarthritic changes to the bone marrow cavities. This observation coincide with *Strassle et al. (2010)* who documented that replacement of subchondral marrow by fibrovascular mesenchymal tissue could be seen rodent models of OA, induced by intra-articular injection of monoiodoacetate (MIA).

Sections of AC in the MSCs treated **subgroup IIIa** (MSCs injected 2 weeks after MIA) showed apparent increase in the AC thickness compared to osteoarthritic group with normal zonation but with hardly identified tide mark. This finding indicates improvement of the osteoarthritic features as a result of intra articular MSCs therapy. This may be explained by the results of *Mokbel et al. (2011)* who stated that the bone marrow-derived MSCs are capable of dividing and differentiating into one of several mesenchymal phenotypes such as osteoblasts, chondrocytes and adipocytes. In addition, these MSCs secrete a variety of cytokines and growth factors that have both paracrine and autocrine activities. These secreted bioactive factors suppress the local immune system, inhibit fibrosis and apoptosis, enhance angiogenesis, and stimulate mitosis and differentiation of tissue- intrinsic reparative or stem cells.

Examination of H&E stained sections of the MSCs treated subgroup IIIa showed proliferating chondrocytes inside lacunae in the transitional zone while the deep zone showed chondrocytes arranged in columns. This finding could be attributed to differentiation of MSCs into chondrocytes. The same results were observed by *Tatebe et al. (2005)* who examined MSCs in articular cartilages and found that some cells exhibited a chondrocyte-like phenotype (rounded shaped surrounded by a lacuna) indicating differentiation of injected MSCs while in other areas cells remained spindle-like (mesenchymal). Thus, they concluded that the local environment of the homing site can induce a chondrogenic phenotype in undifferentiated MSCs.

Sections of the MSCs treated **subgroup IIIa** also revealed few chondrocytes with small dark nuclei with hypereosinophilic cytoplasm. This finding indicates cell death or apoptosis. This could be attributed to the residual destructive effect of MIA in osteoarthritic joints. Examination of H&E sections of AC from **subgroup IIIb** (MSCs injected 4 weeks after MIA) showed proliferation of chondrocytes forming clusters especially in the transitional zone. However, many chondrocytes appeared shrunken with dark nuclei and eosinophilic cytoplasm indicating cell death. The improvement of osteoarthritic changes in subgroup IIIa was better than subgroup IIIb indicating that MSCs injection after 2 weeks was more effective than

MSCs injection after 4 weeks. This finding coincides with *Mokbel et al. (2011)* who detected that the grading scores in earlier treated animals with MSCs were better than those of later treated. It is likely that the cumulative effect of the abnormal load imposed as a result of the severed cartilage resulted in progressive cartilage damage that was not completely prevented by the repair process. So, they concluded that the earlier the injection the better the effect.

On the other hand, *Singh et al. (2014)* examined stem cells as a treatment option for OA and had shown significant improvement both histopathologically and radiologically, compared with control specimens at both 16 and 20 weeks of follow-up and concluded that stem cells were a promising source for treatment of OA even without the use of stem cell culture. However, studies with larger groups and longer follow-up are required to determine the use of stem cells as a therapeutic option.

Examination of H&E stained sections of the AC in the **subgroup IVa** (untreated group 4 weeks after MIA) showed apparent reduction in the articular cartilage thickness compared to control which was more obvious in **subgroup IVb** (untreated group 6 weeks after MIA). This could be approved statistically by a significant decrease of the mean articular cartilage thickness in untreated group (**subgroups IVa & IVb**) compared to control group. Sections from **subgroup IVa** also revealed loss of normal zonation. Many chondrocytes with condensed dark nuclei were observed. While in **subgroup IVb** irregular eroded surface as a result of exfoliation of superficial and transitional zones could be seen with complete loss of zonation and degenerated chondrocytes. These findings suggest worsening of the osteoarthritic changes after longer duration without treatment. This suggestion was based on the finding observed by *Ferreira-Gomes et al. (2012)* who documented that the histopathological findings observed in osteoarthritic animals were dose and time-dependent. Chondrocyte death and loss of intercellular matrix was observed and this was more pronounced and accompanied by a marked decrease of the thickness of the articular cartilage at day 31 after intra articular MIA injection.

Examination of toluidine blue stained sections in control group (**group I**) revealed dense staining of the extracellular matrix of the transitional and deep zones compared to the superficial and calcified zones. This indicate that the proteoglycan content in normal AC is distributed in the transitional and deep zones more than in superficial and calcified zones. These findings coincide with *Bhosale & Richardson (2008)* who reported low concentration of proteoglycans in the superficial zone of AC and abundant proteoglycan in the transitional zone.

Examination of toluidine blue stained sections in **subgroup IIa** (2 weeks after MIA) demonstrated mild to moderate heterogeneous staining of the extracellular matrix with nearly no apparent difference between the different zones while **subgroup IIb** (4 weeks after MIA) showed faint staining of the extracellular matrix of all AC zones compared to control group. These results were confirmed by statistical analysis of the mean optical density of AC matrix in toluidine blue stained sections which revealed that there was a significant decrease of the matrix optical density in the osteoarthritic group (**subgroups IIa & IIb**) compared to the control group. These results regarding the extracellular matrix staining intensity was explained by *Sandell and Aigner (2001)* who documented that matrix degrading enzymes are over expressed in OA resulting in loss of collagen and proteoglycans from the matrix.

Examinations of toluidine blue stained sections of the AC of **subgroup IIIa** (MSCs treated group 2 weeks after MIA) revealed increase in the staining intensity of the extracellular matrix especially in the transitional zone. While in **subgroup IIIb** (treated group 4 weeks after MIA) examination showed increased staining intensity of the transitional and deep zones. There was no significant difference in the mean optical density of AC matrix in toluidine blue stained sections in treated group (**subgroups IIIa & IIIb**) compared to control. These findings could be attributed to the regenerative effect of intra articular injection of MSCs in OA. The same finding was explained by *Horie et al. (2012)* showed increase in toluidine blue staining after MSCs injection with regeneration of cartilage tissue. However, the fate of MSCs by imaging and histology were decreased with time.

Examination of toluidine blue stained sections of the AC in **subgroup IVa** showed mild staining of the extracellular matrix of the AC which became faint in **subgroup IVb**. A significant decrease in the mean optical density of AC matrix in the untreated group (**subgroups IVa & IVb**) compared to control group could be approved statistically. This result could be attributed to the deterioration of OA by longer duration of time. This result was in agreement with *Ferreira-Gomes et al. (2012)* who noticed decrease in proteoglycan staining by day 31 post MIA injection in a rat model of OA. They explained that the severity of the MIA-induced OA has been shown to be concentration and time-dependent.

Examination of collagen type II stained sections in control group (**group I**) revealed strong extracellular immunoreactivity in the superficial zone and moderate immunoreactivity in the transitional zone. The examination also revealed positive immunoreactivity of the extracellular matrix of the

deep zone which had the appearance of bundles that are arranged parallel to the long axis of the AC. The calcified zone showed least immunoreactivity.

This normal variation of immunoreactivity reflects the normal distribution of the collagen fibrils within the AC. This finding coincides with *Ross and Pawlina (2011)* who stated that the superficial zone is a pressure-resistant region that contains numerous flattened chondrocytes surrounded by a condensation of type II collagen fibrils that are arranged in fascicles parallel to the free surface. On the other hand, the collagen fibrils in the transitional zone are less organized with an oblique orientation to the surface. The collagen fibrils are positioned between chondrocytes columns parallel to the long axis of the bone in the deep zone.

The immunohistochemical results of collagen type II in osteoarthritic group (**group II**) showed apparent decrease in the extracellular immunoreactivity in the **subgroup IIa** (2 weeks after MIA) which become more obvious in the **subgroup IIb** (4 weeks after MIA) as compared to control group. The positive immunoreactivity had a patchy interrupted appearance. A significant decrease of the mean area % of collagen II in **subgroups IIa and IIb** compared to control group were confirmed statistically. These results indicate reduction in collagen fibrils as a result of OA. The patchy areas could be attributed to destruction of the collagen fibers resulting in the formation of fibrillated cartilage areas in the AC. This coincides with *Pritzker et al. (2006)* who documented that matrix degradation (loss of matrix stain, collagen fibre rarefaction/collagen fibre condensation) may be observed in the AC matrix during osteoarthritis.

These findings coincide with *Huebner et al. (2010)* who observed that there was a reduction in normal collagen network with apparent cartilage structural damage of the AC in an animal model of experimental OA. They suggested that these histological changes in knee OA were due to collagenase cleavage and disruption of the type II collagen network early in OA disease events. Disruption of this fibrillar network is mediated by specific matrix metalloproteinase (MMP) enzymes that cleave collagen, namely collagenases-1, -2 and -3.

Furthermore, *Taniguchi et al. (2009)* reported that the exact relationship between the degradation of the collagen network and the loss of proteoglycans within the articular cartilage is not known. However, a loosening of the collagen network leads to a loss of proteoglycans and further degradation of the collagen network which may lead to an increase in the water content and subsequent swelling of the articular cartilage.

Immunohistochemical examination of collagen type II stained sections in **subgroup IIIa** (treated group 2 weeks after MIA) showed increased extracellular immunoreactivity with strong immunostaining in the superficial zone and moderate staining in the transitional zone. In the deep zone, the immunoreactivity started to take the appearance of long thick bundles between chondrocytes columns. This finding coincides with *Pritzker et al. (2006)* who stated that the new collagen fibres may be thicker and more birefringent than preexisting fibres.

Examination of **subgroup IIIb** (treated group 4 weeks after MIA) also showed strong extracellular immunoreactivity in the superficial zone, moderate immunoreactivity in the transitional and deep zones and faint immunoreactivity in the calcified zone. Statistical analysis of the mean area % of collagen II showed that there was no significant difference in **subgroup IIIa** and **subgroup IIIb** compared to control. The same finding was explained by *Caplan and Correa (2011)* who stated that the intra-articularly injected MSCs can differentiate into chondrocytes to actively produce extracellular matrix.

Sections immune-stained for collagen type II showed decreased patchy interrupted extracellular immunoreactivity in both **subgroups IVa** (untreated group 4 weeks after MIA) and **IVb** (untreated group 6 weeks after MIA). Statistical analysis of the mean area % of collagen II in the untreated group revealed that there was a significant decrease in **subgroups IVa and IVb** compared to the control group. These results could be attributed to long duration of OA that lead to more deterioration of the pathological features without spontaneous recovery. This result coincides with *Goldberg (2012)* who stated that articular cartilage has significant limitations for repair or regeneration. It does not respond to an injury or disease with the normal inflammatory sequence of events that results in repair of most other tissues.

Conclusion:

- Intra articular injection of MIA is available technique to obtain a model of osteoarthritis in rats' knee joints.
- MSCs are a promising cell source for the regeneration of the AC, they possess chondrogenic differentiation potential and are easy to obtain.
- MSCs have the potential to replace the damaged cartilage with hyaline cartilage through enhancement of proliferation of chondrocytes and formation of collagen II and proteoglycan.
- Early treatment with MSCs was more effective in improvement of osteoarthritic changes than later treatment.

Recommendations

- Further researches are needed in order to more fully understand the mechanism by which MSCs cells provide improvement of osteoarthritis.
- More preclinical and clinical studies are necessary to establish the appropriate conditions and techniques of MSCs application in human.
- Long term risks, such as transformations or mal differentiation associated with MSCs administration should be thoroughly investigated.
- It might be advisable to use intra-articular MSCs injection as therapeutic tool in patients with osteoarthritis.

References:

1. Al-Saffar F J, Ganabadi S, Yaakoub H And Fakurazi S. (2009): Collagenase and sodium iodoacetate-induced experimental osteoarthritis model in Sprague Dawley rats. *Asian Journal of Scientific Research*; 2: 167-179.
2. Andras H, Andreas HG, Henning M, Matej D, Giuseppe F and João EM. (2012): Biomechanical considerations in the pathogenesis of osteoarthritis of the knee. *Knee Surg Sports Traumatol Arthrosc*; 20: 423-435.
3. Bhosale AM and Richardson JB. (2008): Articular cartilage: structure, injuries and review of management. *British Medical Bulletin*; 87: 77-95.
4. Caplan AI and Correa D. (2011): The MSC: an injury drug store. *Cell Stem Cell*; 9:11-15.
5. Coleman CM, Curtin C, Barry FP, O'Flatharta C and Murphy JM. (2010): Mesenchymal stem cells and osteoarthritis: remedy or accomplice? *Hum Gene Ther*; 21:1239-1250.
6. Dieppe PA and Lohmander LS. (2005): Pathogenesis and management of pain in osteoarthritis. *Lancet*; 365: 965-973.
7. Ferreira-Gomes J, Adães S, Sousa R, Mendonça M and Castro-Lopes J. (2012): Dose-dependent expression of neuronal injury markers during experimental osteoarthritis induced by monoiodoacetate in the rat. *Molecular Pain*; 8:50-75.
8. Goldberg V M. (2012): Stem Cells in Osteoarthritis. *HSS osteoarthritis symposium*; 8:59-61.
9. Guzman RE, Evans MG, Bove S, Morenko B and Kilgore K. (2003): Mono-iodoacetate-induced histologic changes in subchondral bone and articular cartilage of rat femorotibial joints: an animal model of osteoarthritis. *Toxicol Pathol*; 31:619-624.
10. Horie M, Choi H, Lee R H, Reger R L, Ylostalo J, Muneta T, Sekiya I., Prockop D.J. (2012): Intra-articular injection of human mesenchymal stem cells (MSCs) promote rat meniscal regeneration by being activated to express Indian hedgehog that enhances expression of type II collagen. *Osteoarthritis and Cartilage*; 20: 1197-1207.
11. Huebner J L, Williamsz J M, Debergx M, Henrotin Y and Krausy V B. (2010): Collagen fibril disruption occurs early in primary guinea pig knee Osteoarthritis. *Osteoarthritis and Cartilage*; 18: 397-405.
12. Kobayashi K, Imaizumi R, Sumichika H, Tanaka H, Goda M, Fukunari A, Komatsu H. (2003): Sodium iodoacetate-induced experimental osteoarthritis and associated pain model in rats. *J Vet Med Sci*; 65:1195-1199.
13. Loeser RF. (2010): Age-related changes in the musculoskeletal system and the development of osteoarthritis. *Clin Geriatr Med*; 26:371-386.
14. Lyons TJ, McClure SF, Stoddart RW and McClure J. (2006): The normal human chondro-osseous junctional region: evidence for contact of uncalcified cartilage with subchondral bone and marrow spaces. *BMC Musculoskelet Disord*; 7: 52-58.
15. Mason RM, Chambers MG, Flannelly J, Gaffen JD, Dudhia J and Bayliss MT. (2001): The STR/ort mouse and its use as a model of osteoarthritis. *Osteoarthritis Cartilage*; 9(2):85-91.
16. Matsumoto T, Cooper GM, Gharaibeh B, Meszaros LB, Li G and Usas A. (2009): Cartilage repair in a rat model of osteoarthritis through intraarticular transplantation of muscle-derived stem cells expressing bone morphogenetic protein 4 and soluble Flt-1. *Arthritis Rheum*; 60: 1390-1405.
17. Mokbel A N, El Tookhy O S, Shamaa A A, Rashed L A, Sabry D and El Sayed A M. (2011): Injection of autologous mesenchymal stem cells in osteoarthritic animal model. *BMC Musculoskeletal Disorders*; 12:259-277.
18. Musumeci G, Loreto C, Carnazza M L and Martinez G. (2011): Characterization of apoptosis in articular cartilage derived from the knee joints of patients with osteoarthritis. *Knee Surg Sports Traumatol Arthrosc*; 19: 307-313.
19. Pritzker KPH, Gay S, Jimenez SA, Ostergaard K, Pelletier JP, Revell PA and Salter D. (2006): Osteoarthritis cartilage histopathology: grading and staging. *Osteo Arthritis and Cartilage*; 14: 13-29.
20. Protol GG, Vasconcelos BC, Fraga SN, Castro CMMB and Andrade ESS. (2011): Development of temporomandibular joint ankylosis in rats using stem cells and bone graft. *Int J Oral Maxillofac Surg*; 40:1414-1420.

21. Ross M H and Pawlina W. (2011): *Histology: A Text and Atlas with Correlated Cell and Molecular Biology*. 6th ed., Philadelphia, Baltimore, New York, London, Buenos Aires, Hong Kong and Tokyo. chapter 7; p:198-216.
22. Sandell LJ and Aigner T. (2001): Articular cartilage and changes in arthritis. An introduction: cell biology of osteoarthritis. *Arthritis Res*; 3:107–113.
23. Singh A, Goel S C, Gupta K K, Kumar M, Arun G R, Patil H, Kumaraswamy V and Jha S. (2014): The role of stem cells in osteoarthritis. An experimental study in rabbits. *Bone Joint Res*; 3:32–37.
24. Strassle BW, Mark L, Leventhal L, Piesla MJ, Jian Li X and Kennedy JD. (2010): Inhibition of osteoclasts prevents cartilage loss and pain in a rat model of degenerative joint disease. *Osteoarthritis Cartilage*; 18:1319-1328.
25. Taniguchi N, Carames B, Ronfani L, Ulmer U, Komiya S and Bianchi ME. (2009): Aging-related loss of the chromatin protein HMGB2 in articular cartilage is linked to reduced cellularity and osteoarthritis. *Proc Natl Acad Sci. U S A*; 106:1181-1186.
26. Tatebe M, Nakamura R, Kagami H, Okada K and Ueda M. (2005): Differentiation of transplanted mesenchymal stem cells in a large osteochondral defect in rabbit. *Cytotherapy*; 7:520-530.
27. Thumboo J, Chew LH and Lewin-Koh SC. (2002): Socioeconomic and psychosocial factors influence pain or physical function in Asian patients with knee or hip osteoarthritis. *Ann Rheum Dis*; 61: 1017-1020.
28. Tuominen U, Blom M, Hirvonen J, Seitsalo S and Lehto M. (2007): The effect of comorbidities on health-related quality of life in patients placed on the waiting list for total joint replacement. *Health Qual Lif Outcomes*; 5: 16-21.

6/23/2015